

## Duodeno-jejunal fistula caused by ingested two magnets : A case report

Bassam A Ayoub\*; Mohammed A Ali; Tahany A Salem; Marwa S Rizk; Salma A Nage; Rash A Ali

### \*Bassam A Ayoub

Department of Pediatric Hepatology, Gastroenterology and Nutrition, National Liver Institute, Menoufia University, Shebin El-koom, Menoufia, Egypt

Tel: +2-048-222-2740; Fax: +2-048-223-4586, Email: bassamayob@yahoo.com

### Abstract

Ingestion of more than one magnet is potentially harmful and should be managed properly. Herein we present a case of duodeno-jejunal fistula in 8-years male child 2 weeks after accidental ingestion of 2 magnets.

### Keywords

magnet; fistula; foreign body; upper endoscopy; X-ray

### Introduction

Foreign body ingestion is a common event in infants and young children [1]. Children's nosiness combined with the availability and variability of toys and tools with magnetic components may result in accidental ingestion of one or more magnets [2].

Ingested single magnet usually pass spontaneously and do not cause serious complications [3]. The harmful effect of ingestion of two or more magnets is caused by ischemic necrosis of enteric tissue trapped in-between magnets attracted to each other [4-7]. This scenario of complicated magnets ingestion is presented here.

### Case Report

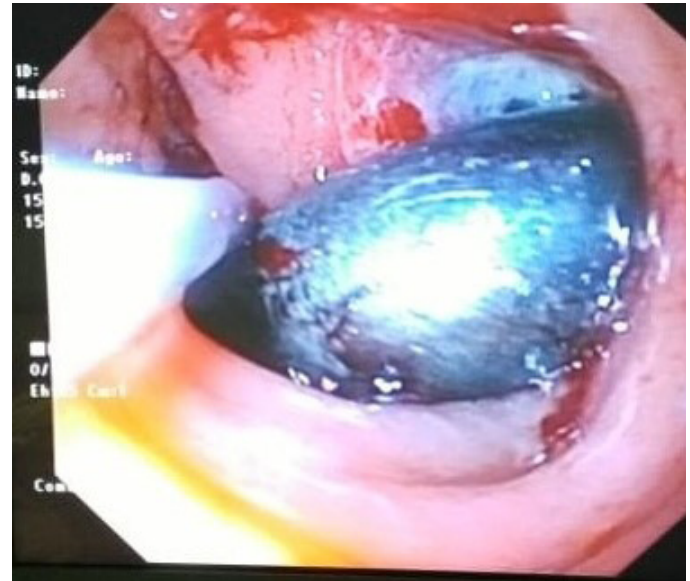
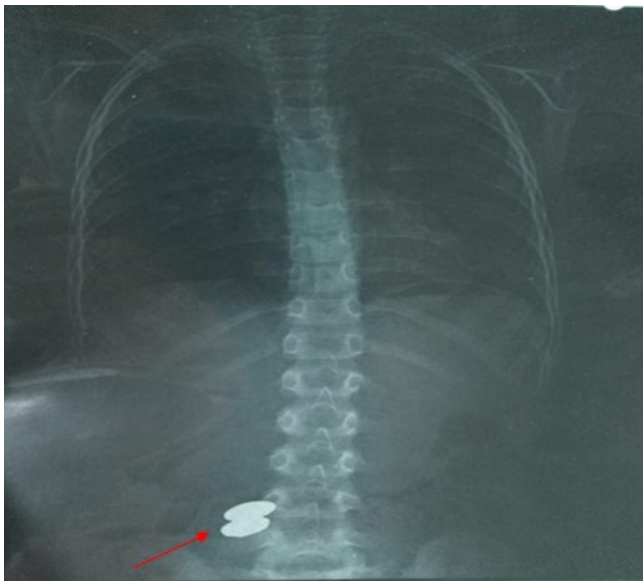
8 years old male child was referred to Department of Pediatric Hepatology and Gastroenterology with history of two magnets ingestion about two weeks before. There was no history of fever, significant abdominal pain, vomiting or bleeding per rectum. The patient was vitally stable with no abdominal distention or tenderness.

Erect abdominal plain X- Ray was done and revealed two radio-opaque objects close to each other on the right side of the intervertebral disc between 4th and 5th lumbar vertebrae (Figure 1).

Upper endoscopy was done and revealed an ovoid shaped magnet about 1.5 x 0.5 cm in the second part of duodenum (Figure 2) which was removed by dormia basket.

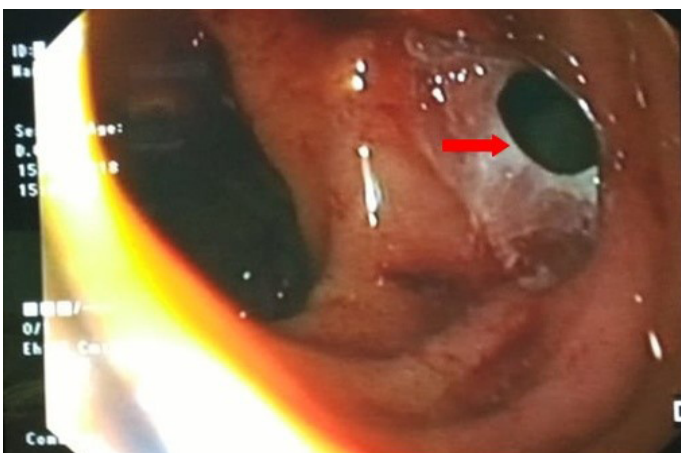
The removal of magnet uncovered a duodeno-jejunal fistula (Figure 3). After endoscopy a contrast enhanced CT was done which confirmed the presence of entero-enteric fistula and another magnet in small intestine and absence of complications like intestinal perforation. The decision after surgical consultation was conservative management and the patient was discharged after follow up erect abdominal X- ray was done.

Follow up of the patient was done in the outpatient clinic one week, one month and three months later and revealed stable vital signs with no significant abdominal pain, vomiting or constipation.



**Figure 1:** Erect abdominal X- ray showing 2 radio-opaque objects (red arrow) on the right side of the intervertebral disc between 4th and 5th lumbar vertebrae

**Figure 2:** A magnet in the 2nd part of duodenum during upper endoscopy



**Figure 3:** An opening about 1 x 0.5 cm in the 2nd part of duodenum (red arrow)

**Figure 4:** One of the 2 magnets after removal from duodenum.

## Discussion

Among ingested foreign bodies magnets seems to have an innocent outcome when compared to sharp objects and button batteries, but this is not the case when more than one magnet were ingested at the same time, and this is due to attraction power between multiple magnets trapping an enteric tissue in-between them, which lead to ischemic necrosis as occurred in this case.

There is no doubt that erect abdominal plain X-ray has a pivotal role in determination of the site of the ingested foreign body, but unfortunately it does not always tell us the truth. That was happened in our case as the position of the radio-opaque objects gave us false impression that the two magnets were out of reach of the upper endoscopy.

So in the case of ingested harmful objects like button batteries, sharp objects and multiple magnets, discision of doing upper endoscopy should not depend, to large extent, on the radiological position of the object.

## Conclusion

Magnets in toys and tools are attractable objects for many infants and young children, and this increases the chance of their ingestion. When ingested, multiple magnets have potential harmful effects.

## Acknowledgments

Thanks to residents and endoscopy unit nurses, Department of Pediatric Hepatology, Gastroenterology and Nutrition, National Liver Institute, Menoufia University for their great effort in this case.

## References

1. Diaconescu S, et al. Foreign bodies ingestion in children: experience of 61 cases in a pediatric gastroenterology unit from Romania. *Gastroenterology research and practice*. 2016.
2. Zachos K, et al. Double jejunoileal fistula after ingestion of magnets. *Journal of Indian Association of Pediatric Surgeons*. 2019; 24: 63.
3. Kim Y, J Hong, SB Moon, Ingestion of multiple magnets: the count does matter. *Journal of Pediatric Surgery Case Reports*. 2014; 2: 130-132.
4. Pogorelić Z, et al. A case of 2-year-old child with entero-enteric fistula following ingestion of 25 magnets. *Acta Medica (Hradec Kralove)*. 2016; 59: 140-2.
5. Mirza MB, et al. Multiple singing magnet ingestion leading to pressure necrosis of the small bowel. *Journal of Indian Association of Pediatric Surgeons*. 2015; 20: 90.
6. Tsai J, et al. Ingestion of magnetic toys: Report of serious complications requiring surgical intervention and a proposed management algorithm. *The Permanente Journal*. 2013; 17: 11.
7. Tavaréz MM, et al. Prevalence, clinical features and management of pediatric magnetic foreign body ingestions. *The Journal of emergency medicine*, 2013; 44: 261-268.

**Manuscript Information:** Received: April 05, 2019; Accepted: May 21, 2019; Published: May 31, 2019

**Authors Information:** Bassam A Ayoub<sup>1\*</sup>; Mohammed A Ali<sup>1</sup>; Tahany A Salem<sup>1</sup>; Marwa S Rizk<sup>1</sup>; Salma A Nage<sup>1</sup>; Rash A Ali<sup>2</sup>

<sup>1</sup>Department of Pediatric Hepatology, Gastroenterology and Nutrition, National Liver Institute, Menoufia University, Shebin El-Koom, Menoufia, Egypt

<sup>2</sup>Department of Radiology, National Liver Institute, Menoufia University, Shebin El-Koom, Menoufia, Egypt

**Citation:** Ayoub BA, Ali MA, Salem TA, Rizk MS, Nage SA, Ali RA. Duodeno-jejunal fistula caused by ingested two magnets : A case report. Open J Clin Med Case Rep. 2019; 1548.

**Copy right statement:** Content published in the journal follows Creative Commons Attribution License (<http://creativecommons.org/licenses/by/4.0>). © **Ayoub BA 2019**

**About the Journal:** Open Journal of Clinical and Medical Case Reports is an international, open access, peer reviewed Journal focusing exclusively on case reports covering all areas of clinical & medical sciences.

Visit the journal website at [www.jclinmedcasereports.com](http://www.jclinmedcasereports.com)

For reprints and other information, contact [info@jclinmedcasereports.com](mailto:info@jclinmedcasereports.com)