

## Intra-abdominal foreign body

Cristina Monteiro\*; Mariana Leite; Bruno Ribeiro da Silva; Alberto Midões

### \*Cristina Monteiro

General Surgery of Local Health Unit of Alto Minho - Santa Luzia Hospital, Rua Arquiteto André Soares, 92 - Bloco 1A H11 4935-165 Viana do Castelo, Portugal

Phone: 0035-1914-202-312; Email: cristina\_f\_monteiro@hotmail.com

### Description

The authors present a case of a 70-year-old man with history of previous cholecystectomy in 1999. He was first sent to the hospital due to abdominal CT findings of a mass of 13 cm of diameter (figure 1) compatible with a Gastrointestinal Stromal Tumor. He had a palpable abdominal mass at physical examination and no symptomatology associated. Surgery was proposed, and the patient accepted.

During the procedure a large mass was identified in the anterior face of the greater curvature of the stomach (figure 2) and an atypical gastrectomy was performed.

The histopathological exam revealed a Textiloma (figure 3).

A Textiloma is a foreign body left in the abdominal cavity after a surgery. Regardless of all precautions adopted by the surgical teams, the international reported incidence is 1 in 1500 laparotomies. The clinical presentation can be acute (abscess or fistulae formation in the immediate postoperative period) or chronic (aseptic granuloma evolution through years till a well encapsulated mass formation).

When a Textiloma is diagnosed it must be removed. Textilomas have health and legal implications and to minimize these situations, it is necessary the commitment of all surgical team. It is important to emphasize the importance of the surgical check list and surgical count.

Figures

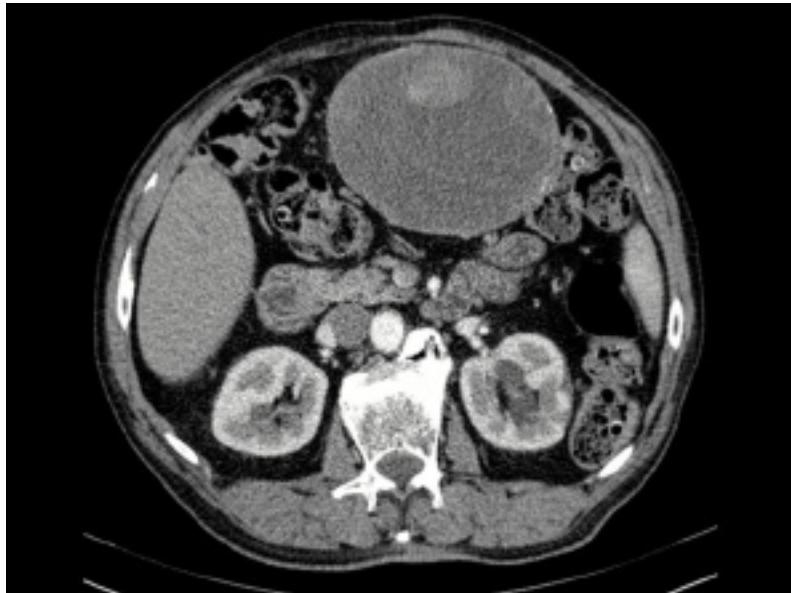


Figure 1: CT scan showing abdominal mass.

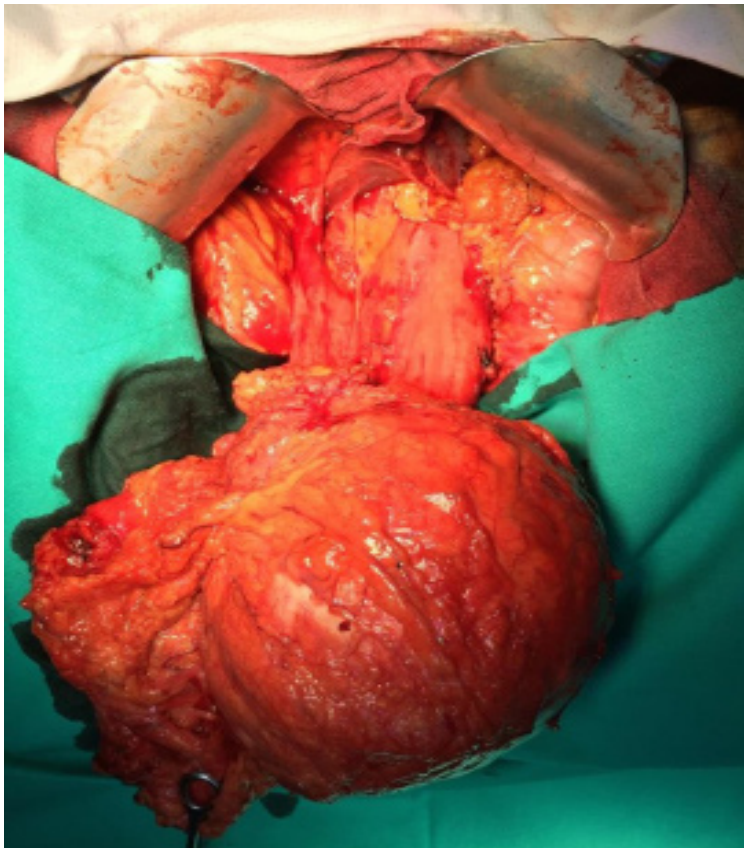
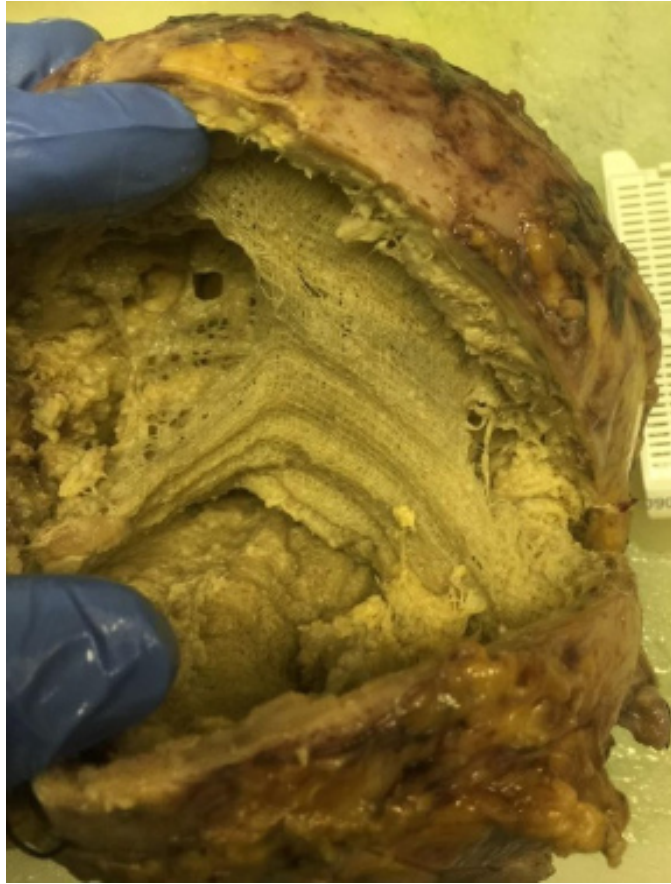
Figure 2: Large mass in the anterior face of the greater curvature of the stomach.



**Figure 3:** Textiloma

**Manuscript Information:** Received: December 03, 2018; Accepted: February 05, 2019; Published: February 28, 2019

**Authors Information:** Cristina Monteiro; Mariana Leite; Bruno Ribeiro da Silva; Alberto Midões

General Surgery of Unidade Local de Saúde do Alto Minho – Hospital de Santa Luzia, Estrada de Santa Luzia, Viana do Castelo, Portugal

**Citation:** Monteiro C, Leite M, da Silva BR, Midões A. Intra-abdominal foreign body. Open J Clin Med Case Rep. 2019; 1510.

**Copy right statement:** Content published in the journal follows Creative Commons Attribution License (<http://creativecommons.org/licenses/by/4.0>). © Monteiro C 2019

**About the Journal:** Open Journal of Clinical and Medical Case Reports is an international, open access, peer reviewed Journal focusing exclusively on case reports covering all areas of clinical & medical sciences.

Visit the journal website at [www.jclinmedcasereports.com](http://www.jclinmedcasereports.com)

For reprints and other information, contact [info@jclinmedcasereports.com](mailto:info@jclinmedcasereports.com)