

Primary Raynaud's phenomenon and contact dermatitis: A brief report

*Sergii Vasyliuk

Vascular Surgeon, Ivano-Frankivsk National Medical University, Ukraine
Phone: +38098-6058-640; Email: siversan@gmail.com

Abstract

We describe a 26-years-old female with primary Raynaud's phenomenon who developed a contact dermatitis on her right-hand fingers (II, III, IV, V) caused by 'Nivea®' cream for her face during the winter period. There was no rash or any symptoms on her face, which confirms that primary Raynaud's phenomenon during cold weather may increase susceptibility to contact dermatitis. We have excluded other possible diseases with the help of laboratory analyses and instrumental findings. After stopping the cream her symptoms disappeared. To our knowledge, this is the first described clinical case of primary Raynaud's phenomenon, which shows that the progression of the disease may increase the susceptibility to contact dermatitis.

Keywords

Raynaud's disease; contact dermatitis; case study

Introduction

Primary Raynaud's phenomenon is a disease, which is characterized by symmetrical bilateral arterial spasms of the fingers and is manifested by paleness, pain, and paresthesia without clear etiology [1]. We could not find any articles related to primary Raynaud's phenomenon and its susceptibility to contact dermatitis. So this article will be the first which describes their relationship.

Case Presentation

A 26-year-old female presented to the primary care physician in the early December 2017 with complaints of red, non-tender spots which appeared on the II and V fingers of her right hand. She is an office worker and works on a computer all day long. The physician performed a complete blood count analysis which was normal. He prescribed diclofenac gel for ten days. Nevertheless, after ten days of treatment, the symptoms worsened: the spots did not disappear and the fingers became swollen and painful. The primary care physician referred her to the dermatologist.

The dermatologist made the diagnosis of atopic dermatitis and prescribed her fluticasone propionate cream for 14 days. The cream has helped her only for an hour or two, and despite its usage, the symptoms still worsened.

After 14 days the patient again came to the primary care physician because the symptoms worsened and she had very painful and swollen II, IV, V fingers. He had sent her to the rheumatologist.

Rheumatologist did the X-ray of her hand and performed laboratory studies. The X-ray of her hand did not reveal any changes. Laboratory studies reveal negative seromucoid, negative rheumatoid factor, negative C-reactive protein, and negative antistreptolysin O (ASO). The rheumatologist prescribed her meloxicam for ten days.

After ten days meloxicam didn't help her. She went again to the primary care physician, who sent her to the vascular surgeon because she has had Primary Raynaud's phenomenon over the last three years.

The patient presented to the vascular surgeon on January 22, 2018 with complaints of red swollen spots, burning pain on her II, III, IV and V fingers of the right hand over the last two months (Fig.1). Because the symptoms were present only on her right hand the physician excluded that the cause is primary Raynaud's phenomenon because primary Raynaud's phenomenon involves two hands. There were no symptoms on her left hand except coldness, paleness, and numbness of her fingers. Physical examination reveals severe general tenderness of II, III, IV and V fingers of the right hand, restricted movements on fingers joints and severe swollen fingers. The physician decides to check systemic diseases and performed antibodies to ANA, RNP, SCL-70, Jo-1, Centromere B, Ribosomal protein, SS-A, SS-B, SM, SM/RNP, anti-dsDNA, Chromatin, which were all negative.

The patient is right-handed and she has the symptoms only on the fingers of her right hand, so the doctor asked if she uses any cream for the face. She said that she uses 'Nivea[®]' cream for her face over the last six months. The vascular surgeon asked her to stop using any cream for a week and rescheduled the visit. After one week the patient presented with dry fingers, however, the swollenness, redness, and pain disappeared on her fingers (Fig.2).

Discussion

We conclude that during the winter season her primary Raynaud's phenomenon progressed and lead to some effects which caused dermatitis to her cream for face. To our knowledge, this is the first described clinical case, which shows that the primary Raynaud's phenomenon may increase susceptibility to different agents and lead to the contact dermatitis.

Contact dermatitis is mainly divided into allergic contact dermatitis and irritant contact dermatitis. Allergic contact dermatitis is caused by allergen-specific T lymphocytes. The symptoms develop shortly after reexposure to low concentrations of allergen. Irritant contact dermatitis develops after prolonged and repeated exposure to irritants. Allergen-specific lymphocytes not involved in pathogenesis [2].

We think that the most likely cause of patient's symptoms was chronic (cumulative) irritant contact dermatitis. We suppose that because the patient is right-handed, the exposure to the topical cream (irritant) was more common to her right hand. It seems that primary Raynaud's phenomenon decreases the regeneration capabilities of skin, which prolonged the time to completely restore after irritant. Therefore consequence of multiple episodes of subthreshold damage to her skin leads to appearing of symptoms on her right hand, which is weakened by Raynaud's phenomenon, but not on her face.

The author recommends excluding all possible topical substances, which the patient is used, prior to administering any drugs or laboratory analyses for systemic diseases.

Figures

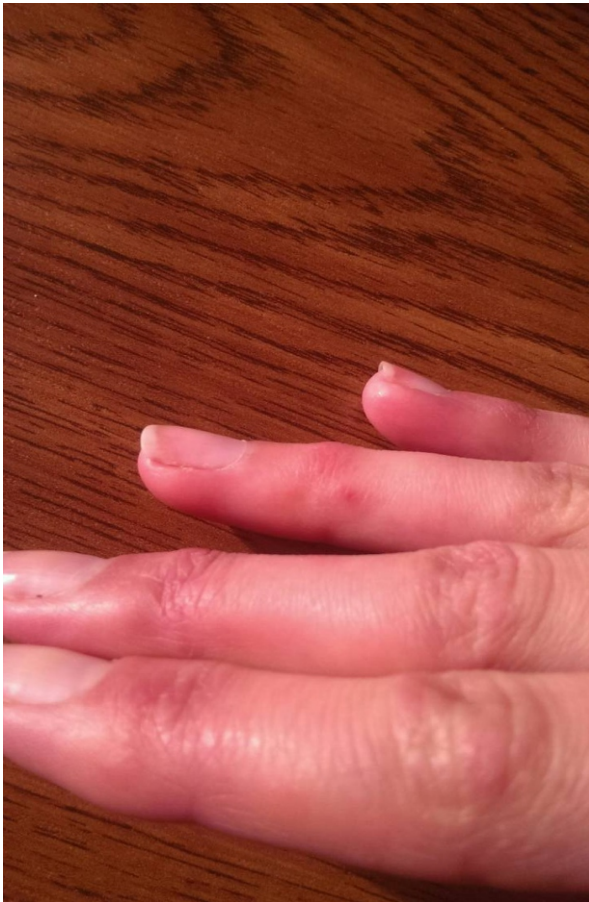

Figure 1




Figure 2

References

1. Wigley FM, Flavahan NA. Raynaud's phenomenon. *New England Journal of Medicine*. 2016; 375(6): 556-565.
2. Brasch J, Becker D, Aberer W, Bircher A, Kränke B, Jung K, Przybilla B, Biedermann T, Werfel T, John SM, Elsner P. Guideline contact dermatitis. *Allergo journal international*. 2014 Jun 1;23(4):126-38.

Manuscript Information: Received: September 27, 2018; Accepted: December 28, 2018; Published: December 31, 2018

Authors Information: Sergii Vasyliuk

Vascular Surgeon, Ivano-Frankivsk National Medical University, Ukraine

Citation: Vasyliuk S. Primary Raynaud's phenomenon and contact dermatitis: A brief report. *Open J Clin Med Case Rep*. 2018; 1502.

Copy right statement: Content published in the journal follows Creative Commons Attribution License (<http://creativecommons.org/licenses/by/4.0>). © Vasyliuk S 2018

Journal: *Open Journal of Clinical and Medical Case Reports* is an international, open access, peer reviewed Journal focusing exclusively on case reports covering all areas of clinical & medical sciences.

Visit the journal website at www.jclinmedcasereports.com

For reprints and other information, contact editorial office at info@jclinmedcasereports.com