

## Massive pulmonary embolism presenting as syncope and treated successfully with tenecteplase: An interested case report

Michail Fosteris\*; Pantelis Koutoukas; Panagiotis Georgantas ; Andreas Lamprou

\*Michail Fosteris

Cardiology Department, Sparti General Hospital, Dioskouron 139, 23100, Sparti, Greece  
Phone: 00306972914909; Email: mixkosfos@yahoo.gr

### Abstract

We report a 72 years old woman presenting to emergency department of our hospital because of syncope. A sharp thoracic pain is referred a day before. Immediate cardiac ultrasound revealed McConnell's sign and a chest computed tomography was ordered which confirmed the diagnosis of pulmonary embolism. Because of hemodynamic instability thrombolysis was performed using tenecteplase. Early spectacular improvement of the patient was observed with hemodynamic stabilization and reduction of right ventricular dysfunction. The patient was discharged in good condition after two weeks of hospitalization remaining uncomplicated till now taking oral anticoagulation with apixaban. The presented clinical case report is worthy of note since syncope is not a classic symptom of pulmonary embolism and our patient had neither tachycardia neither tachypnoea. Furthermore, the role of echocardiography in diagnosis is emphasized and tenecteplase seems to offer salvation to an hemodynamic instable patient.

### Keywords

massive pulmonary embolism; tenecteplase; McCollen's sign; syncope; apixaban

### Introduction

Pulmonary embolism is still difficult to diagnose at emergency department due and syncope is not very usual symptom. Echocardiography is very useful in order to help physician to suspect pulmonary embolism and order more specific exercises. Thrombolysis is the only way when shock exists but according to guidelines the third-generation thrombolytic agents haven't yet been approved.

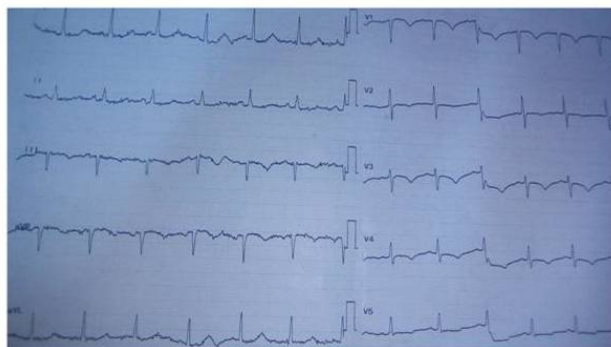
A 73 year old woman presented to emergency department with reported syncope, while a one-day history of constant sharp right hemithoracic pain of pleuritic type was mentioned. The pain was accompanied by occasional nausea. A review to her medical history revealed a fall two weeks before which made her to reduce mobility as she was on bed the most of the daytime. Because of the fall the computed tomography (CT) of the brain showed a cephalohematoma without a recognized brain injury. The patient was known to suffer from diabetes mellitus type II on glimepiride and metformin, hypertension on nebivolol, olmesartan-hydrochlorothiazide and lecardipine, hyperlipidemia on atorvastatin and fenofibrate, hyperuricemia on allopurinol and depression on citalopram and

bromazepam. She was also taking acetylsalicylic acid without profound reason. Her medical history was fulfilled with hysterectomy, left knee arthroplasty and left nephrectomy.

## Discussion

Physical examination found an oriented patient with no fever but low oxygenation (<90% on room air) and hypotension 93/71 mm Hg. There was no tachycardia probably due to use of beta blocker medicine. Her respiratory rate was 20 breaths/min and pulse 85 beats/min. No peripheral edema but dilatation of jugular vein. Her chest wall was clear on auscultation and normal heart sounds with no additional sounds were heard.

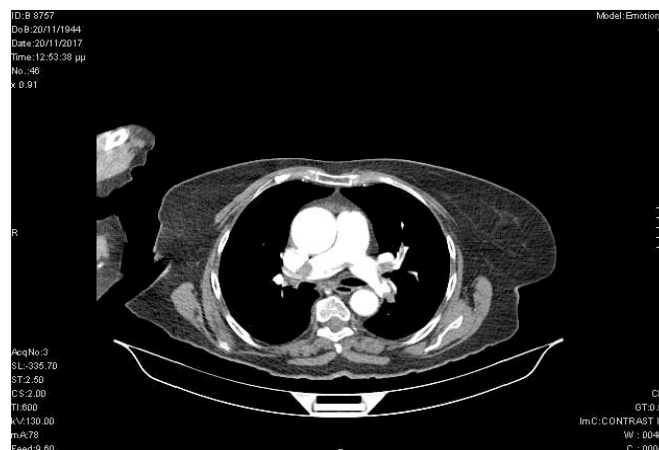
The initial 12 lead electrocardiogram showed a sinus rhythm of 83 beats per minute with T inversion in V1 to V5 (Figure 1). There was no S1Q3T3 pattern. Laboratory work-up revealed a neutrophilic leukocytosis, affected kidney function with calculated glomerular filtration rate of 30 mL/min/1.73 m<sup>2</sup>, elevated high sensitive troponin level and slightly elevated c-reactive protein.



**Figure 1:** inversion of T in V1 to V5

Due to the whole clinical presentation of the patient an emergency cardiac ultrasound was performed raising the question of a pulmonary embolism or an infraction of the right ventricular. There were three week risk factors for pulmonary embolism bed rest for over three days, diabetes mellitus and hypertension. The findings of the cardiac ultrasound was a dilated right ventricular with diffuse hypokinesis with apical hyper contractility (McConnell's sign), mild tricuspid regurgitation with elevated pulmonary pressure estimated at 45mmHg. The left ventricular was normal with no hypokinesis and ejection fraction of 60%. A known dilatation of ascending aorta was detected of 46mm.

Having this data a chest computed tomography was ordered and its findings confirmed massive pulmonary embolism (Figure 2).

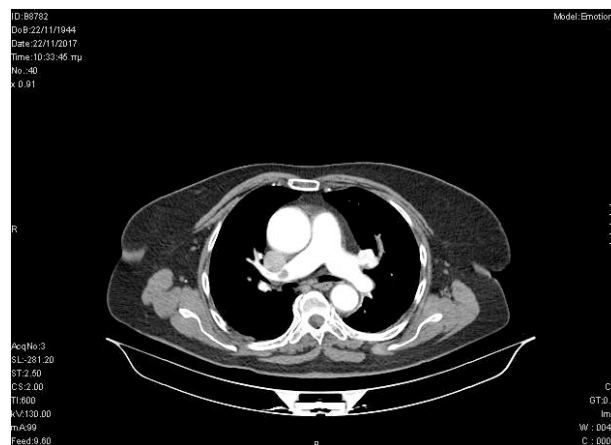

**Figure 2:** bilateral occlusion of main pulmonary arteries

After the diagnosis was made an immediately dose of fondaparinux was given and the patient was admitted to internal medicine treatment. Few hours later the patient became confused with respiratory distress and severe hypotension of 75/40mmHg. Venturi mask was placed and an infusion of normal saline and noradrenaline as inotrope was started. Then the patient was transferred to the cardiology department and the intensive care unit in order to have better monitoring. As the patient remained unstable and hemodynamic collapsed-instead of the infusion of inotrope-it was decided to thrombolys. Tenecteplase was used in dosage like myocardial infarction (30mg according to the body weight of the patient).

After thrombolysis the improvement was spectacular with immediate reduction of right ventricular dysfunction and increase of cardiac output shown on cardiac ultrasound. Almost one hour later the patient did not need inotrope or high oxygen mixtures anymore and she was on nasal cannula.

A new chest computed tomography was held two days after thrombolysis showing bilateral elimination of pulmonary artery occlusion mainly at the left main branches (Figure 3).



**Figure 3:** visible improvement two days later

Since the infusion of the thrombolytic agent was made from a central venous catheter placed into right femoral vein, a large hematoma of right thigh appeared the next day. At the same time there was a drop in hematocrit, so a transfusion of packed red blood cells and fresh frozen plasma were ordered. Surgeon was consulted and the possibility of pseudoaneurysm was suggested but it was not confirmed. The hematoma disappeared gradually and the hematocrit was stabilized.

At first and for five days a daily dose of 7.5mg of fondaparinux was given and then apixaban was started at doses according to the AMPLIFY trial as 10mg twice for a week and then 5mg twice for at least six months. The patient is supposed to be in high risk of recurrent pulmonary embolism so an extended taking of anticoagulation is proposed.

After the first three days the patient became hemodynamic stable without any major complication and at the sixth day of hospitalization she started to walk. The patient was discharged after two weeks of hospitalization and she remains stable until now. Echocardiogram and electrocardiogram were normal at the last reevaluation after three months from discharge.

## Discussion

Our case highlights several issues about the diagnosis and treatment of massive pulmonary embolism. First of all, syncope is not a frequent presentation of a patient suffering from pulmonary

embolism while the prevalence of pulmonary embolism among patients presented to the emergency department as syncope is estimated to be about 17.3%. Syncope is probably the result of poor cardiac output due to obstruction of the most proximal pulmonary arteries. The diagnosis may escape in some cases and syncope should have a careful work-up [1,2].

The method of choice to confirm the diagnosis of pulmonary angiography is multi-detector computed tomography, but echocardiography plays a crucial role in diagnostic strategy. It was found that McConnell's sign is 100% specific for acute pulmonary embolism in patients without known previous cardiorespiratory diseases. On the other hand, it is not sensitive since more than half of the cases may not develop this sign [3].

Furthermore, thrombolysis is a challenge and there aren't yet specific doses for pulmonary embolism. It seems that tenecteplase as a single-dose is the best choice but at present none of the third-generation thrombolytic agents is approved for use in pulmonary embolism according to official guidelines. There is no doubt that recanalization is the only way when hemodynamic collapse occurs. Mortality is higher for patients with "major" pulmonary embolism; registry data indicate in-hospital mortality of up to 30% in patients with acute pulmonary embolism who are hemodynamically unstable at presentation [4]. Several trials showed favorable results for thrombolytic agents versus heparin, like PAIMS 2 and TOPCOAT [5,6]. As far as the dosage is concerned the same doses like myocardial infarction are used and single-bolus tenecteplase is associated with reduction of right ventricular dysfunction in one daytime [7]. In conclusion a large meta-analysis showed that a clear benefit is suggested among those at highest risk of recurrence or death, in particular, patients with major pulmonary embolus who present with hemodynamic instability [8].

Finally, there is a question for the duration of anticoagulation for this patient. It seems that three months according to guidelines is a short period and as this patient is considered to have a high risk of recurrent pulmonary embolism maybe an extended treatment is better. Results from AMPLIFY Extension study are encouraged [9].

## References

1. Thames MD, Alpert JS, Dalen JE. Syncope in patients with pulmonary embolism. *JAMA*. 1977; 238: 2509–11.
2. Prandoni P, Lensing AWA, Prins MH, Ciammaichella M, Perlati M, Mumoli N, et al. Prevalence of Pulmonary Embolism among Patients Hospitalized for Syncope. *N Engl J Med*. 2016; 375: 1524–31.
3. Kurzyna. Disturbed Right Ventricular Ejection Pattern as a New Doppler Echocardiographic Sign of Acute Pulmonary Embolism. *Am J Cardiology*. 2002; 90: 507–11.
4. Kasper W, Konstantinides S, Geibel A, Olschewski M, Heinrich F, Grosser KD, et al. Management strategies and determinants of outcome in acute major pulmonary embolism: Results of a multicenter registry. *J Am Coll Cardiol*. 1997; 30: 1165–71.
5. Dalla-Volta S, Palla A, Santolicandro A, Giuntini C, Pengo V, Visioli O, et al. PAIMS 2: Alteplase combined with heparin versus heparin in the treatment of acute pulmonary embolism. Plasminogen activator Italian multicenter study 2. *J Am Coll Cardiol*. 1992; 20: 520–6.
6. Kline JA, Nordenholz KE, Courtney DM, Kabrhel C, Jones AE, Rondina MT, et al. Treatment of submassive pulmonary embolism with tenecteplase or placebo: cardiopulmonary outcomes at three months (TOPCOAT): Multicenter double-blind, placebo-controlled randomized trial. *J Thromb Haemost* 2014. Apr; 12:

459-68.

7. Becattini C, Agnelli G, Salvi A, Grifoni S, Pancaldi LG, Enea I, et al. Bolus tenecteplase for right ventricle dysfunction in hemodynamically stable patients with pulmonary embolism. *Thromb Res.* 2010; 125: e82-6.
8. Wan S, Quinlan DJ, Agnelli G, Eikelboom JW. Thrombolysis compared with heparin for the initial treatment of pulmonary embolism: a meta-analysis of the randomized controlled trials. *Circulation.* 2004; 110: 744–9.
9. Konstantinides SV, Torbicki A, Agnelli G, Danchin N, Fitzmaurice D, Galie N, et al. *European Heart Journal.* 2014; 35: 3033–80.

**Manuscript Information:** Received: April 20, 2018; Accepted: August 20, 2018; Published: August 31, 2018

**Authors Information:** Michail Fosteris<sup>1\*</sup>; Pantelis Koutoukas<sup>2</sup>; Panagiotis Georgantas<sup>2</sup>; Andreas Lamprou<sup>1</sup>

<sup>1</sup>Cardiology Department, Sparti General Hospital, Greece.

<sup>2</sup>Internal Medicine Department, Sparti General Hospital, Greece.

**Citation:** Fosteris M, Koutoukas P, Georgantas P, Lamprou A. Massive pulmonary embolism presenting as syncope and treated successfully with tenecteplase: An interested case report. *Open J Clin Med Case Rep.* 2018; 1451.

**Copy right statement:** Content published in the journal follows Creative Commons Attribution License (<http://creativecommons.org/licenses/by/4.0>). © **Fosteris M 2018**

Journal: *Open Journal of Clinical and Medical Case Reports* is an international, open access, peer reviewed Journal focusing exclusively on case reports covering all areas of clinical & medical sciences.

Visit the journal website at [www.jclinmedcasereports.com](http://www.jclinmedcasereports.com)

For reprints and other information, contact editorial office at [info@jclinmedcasereports.com](mailto:info@jclinmedcasereports.com)