

Transanal endoscopic resection of high rectal lesions; should we extend our indications?

Islam H Metwally*; Osama Eldamshety

*Islam H Metwally

Surgical oncology unit, Oncology center Mansoura University, Geehan Street, Mansoura city, Dakahlia governorate-35516, Egypt

Email: drislamhany@mans.edu.eg

Abstract

Transanal resection of rectal lesions is an integral skill in the current oncology practice. Our patient suffered a high rectal polypoid mass which was successfully treated by a transanal endoscopic approach. Guide lines restriction for anal verge-tumour distance is debated.

Keywords

transanal; TEO; TEM; upper rectum; rectal cancer

Background

Benign rectal lesions (adenomas and polyps), precancerous lesions (dysplasia), as well as, early rectal cancer (T1 sm1-2 mainly) were used to be treated through Park's transanal excision (TAE) [1]. However, 34 years earlier Gerhard Buess introduced his special approach, transanal endoscopic microsurgery (TEM). It slowly takes over the place of the old TAE with proven superiority (both oncologic and technical) in many studies [2-4]. Afterward Storz introduced the transanal endoscopic operation (TEO) [5], and then in 2009 Atallah et al. invented the transanal minimally invasive surgery (TAMIS) technique [6]. These recently collectively called transanal endoscopic surgery (TES), had opened a new way for extending the indications of the transanal approach for rectal lesions [7].

The NCCN guidelines (version 3. 2017) suggest the following indications for the transanal excision of rectal cancer; lesion should be within 8 cm of the anal verge, small < 3cm in diameter, < 30% of the circumference of the rectal wall, grade 1 or 2 tumours, tumour staged T1N0, mobile tumours, free margin > 3mm, and no lymphovascular invasion nor perineural invasion [8]. Many of these restrictions are debated in literature [9]. Here in our case we emphasis on the height or the distance of the lesion from the anal verge. Feasibility while managing a special patient with a query malignant nature polyp located 17cm from the anal verge is discussed.

Case Presentation

Male patient aged 51 years old, with a body mass index (BMI) 28 and medically free. He had a history of total colectomy and direct illeo-rectal anastomosis a year earlier (February 2016) in the private sector for synchronous colon cancer with postoperative pathology showing GII adenocarcinoma

with mucinous component in filtrating down to the subserosa (T3N0M0) with no lymphovascular nor neural invasion and free safety margins. Thereafter, he received 6 cycles of adjuvant chemotherapy (FOLFOX). Nine months later a routine follow up computerized tomography (CT) showed a cystic lesion in the liver for which a positron emission tomography (PET/CT) was done revealing a simple hepatic cyst, but with a left hypochondrial peritoneal nodule 1.6x1.1cm and a hypermetabolic upper rectal polyp lesion 13 cm from anal verge 1.6x1.7cm (SUV 48). Colonoscopy was done twice (with 2 month interval) the first showed a polyp 17cm from the anal verge, biopsied tubulovillous adenoma with high grade dysplasia. However, the second colonoscopic biopsy showed a low grade dysplasia. CEA and CA19-9 were within the normal. Under general anaesthesia and after adhesiolysis, through a small upper midline incision, exploration of all abdominal and pelvic quadrants and surface of the liver and spleen was negative (no deposits). There was no clinical peritoneal disease. Afterwards, we shifted to a lithotomy position and introduced the TEO ® platform (Karl Storz, Tuttlingen, Germany), after cleansing of the anal canal (**figure 1**). A polypoid lesion in the posterior wall about 17cm from anal verge was identified (**figure 2**). Then, we injected methylene blue submucosal to this lesion. Using a monopolar diathermy the polypoid mass was dissected in a submucosal plane. Further safety margins were taken all around. The procedure ended by insertion of a Foley's catheter transanal for hemostasis, with a Betadine pack. Finally, closure of the abdominal wall and the skin was done. The procedure took 195 minutes. Unfortunately, significant bleeding developed a day after, affecting hemodynamics, with blood haemoglobin falling 2 gram/dl and failed control by packing. Subsequently, 4 days later we underwent a TEO re-exploration of the bed, where large blood clots were washed and a spurter at the edge of the resultant ulcer was found which was controlled by bipolar diathermy coagulation and re-packing. Gross pathology showed rubbery greyish polypoidal mass measuring 2.3x2.1x0.5cm, while histopathology diagnosed as a tubulovillous adenoma with grade II dysplasia and free safety margins.

Discussion

The definition of the rectum varies from anatomists to surgeons. The anatomical rectum extends from the 3rd sacral piece to the anorectal ring (about 12cm), but the surgical rectum extends from the sacral promontory downwards (about 16 +/- 2cm). Upper rectum is that above the peritoneal reflection (about 10cm from the anal verge) [10].

In the light of the known morbidity and mortality of the conventional radical surgeries (low & ultralow anterior, intersphincteric, and abdominoperineal resections) and the low probability of nodal spread in T1 tumours (3-12%), endoscopic local excision is increasingly used for these lesions [11]. Endoscopic local excision procedures are shown superior, in selected cases, to major surgeries in terms of operating time, blood loss, hospitalization, intestinal leak and mortality [12].

Most case series and trials emphasis on lesions within 8cm or slight more (<10cm) from the anal verge. However, several studies discussed the feasibility of resection of higher lesions obviating or minimizing the fear from peritoneal perforations [9,13,14]. Obviously, the current rigid endoscopes TEM and TEO are available in up to 20cm length reaching easily at and beyond the rectosigmoid junction. Molina et al. in an interesting study showed that peritoneal perforation in higher tumours is still low and feasible for transanal repair either by the TAMIS technique or by shifting to a rigid platform (TEM or TEO) if not used from the start [15].

Actually the commonest complication, far in practice, of transanal endoscopic surgery is the postoperative haemorrhage, as encountered in our patient. In the other hand, it was never reported fatal and almost always controlled with another endoscopic intervention (redo TES as described in our patient or conventional proctoscopy) [16].

Another issue we would clearly identify from our practice that in a no way did a previous abdominal colon or rectal surgery hinder a transanal approach, actually this is another advantage over the difficult abdominal access in such cases.

Conclusion

Transanal endoscopic surgery has no height limitations, as long as, instruments can reach the target lesion. A higher complication rate should be predicted, but transanal approaches with/without laparoscopic assistance can manage in most circumstances. International colorectal guidelines should be modified to withst and the current extended indications in practice.

Acknowledgement

We would like to acknowledge dr/Ashraf Waly, specialist of surgical oncology in Meet Ghamr cancer center, for his effort in diagnosing and proper managing of this case.

Figures

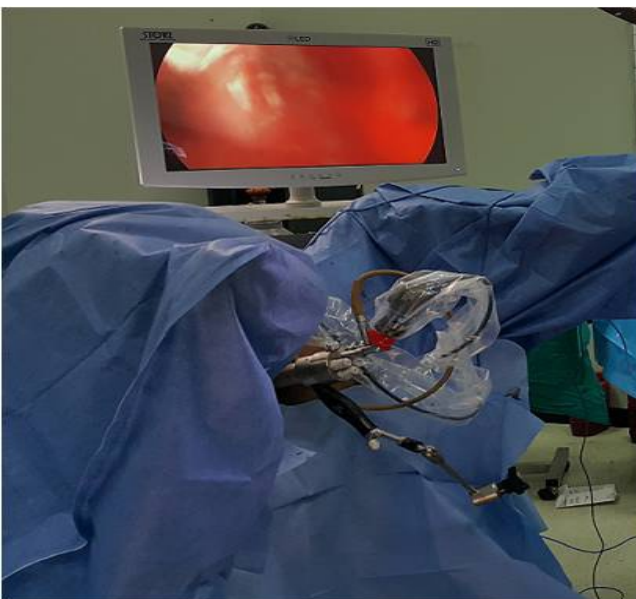


Figure 1: Position of the patient, the setting of the TEO platform and the monitor in the operative field.

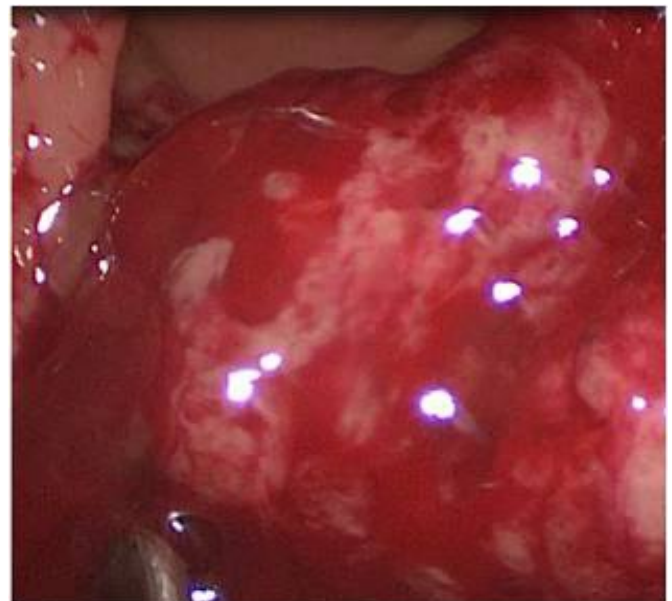


Figure 2: Friable mass, bleeding on touch, as seen with the TEO platform with the 15cm rectoscope maximally inserted into the anal canal.

References

1. Han J, Noh GT, Cheong C, Cho MS, Hur H, Min BS, et al. Transanal Endoscopic Operation Versus Conventional Transanal Excision for Rectal Tumors: Case-Matched Study with Propensity Score Matching. *World journal of surgery*. 2017.
2. de Graaf EJ, Burger JW, van Ijsseldijk AL, Tetteroo GW, Dawson I, Hop WC. Transanal endoscopic microsurgery is superior to transanal excision of rectal adenomas. *Colorectal disease : the official journal of the Association of Coloproctology of Great Britain and Ireland*. 2011;13 (7): 762-7.

3. Clancy C, Burke JP, Albert MR, O'Connell PR, Winter DC. Transanal endoscopic microsurgery versus standard transanal excision for the removal of rectal neoplasms: a systematic review and meta-analysis. *Diseases of the colon and rectum*. 2015; 58 (2): 254-61.
4. Hakiman H, Pendola M, Fleshman JW. Replacing Transanal Excision with Transanal Endoscopic Microsurgery and/or Transanal Minimally Invasive Surgery for Early Rectal Cancer. *Clinics in colon and rectal surgery*. 2015;28 (1): 38-42.
5. Rocha JJ, Feres O. Transanal endoscopic operation: a new proposal. *Acta cirurgica brasileira. Suppl discussion*. 2008; 23 (1): 93-104.
6. Atallah S, Albert M, Larach S. Transanal minimally invasive surgery: a giant leap forward. *Surgical endoscopy*. 2010;24 (9): 2200-5.
7. Zhang C SP. Current Endoluminal Approaches: Transanal endoscopic microsurgery, transanal minimally invasive surgery and transanal total mesorectal excision. . In: SW RH, Rivadeneira DE, Steele SR, Feingold DL, editor. *Advanced Colonoscopy and Endoluminal Surgery*: Springer; 2017: 217-44.
8. Network NCC. NCCN Clinical Practice Guidelines in Oncology. Rectal cancer Version 3.2017. 2017 March 13. Available from: https://www.nccn.org/professionals/physician_gls/pdf/rectal.pdf.
9. Saget A, Maggiori L, Petruciani N, Ferron M, Panis Y. Is there a limit to transanal endoscopic surgery? A comparative study between standard and technically challenging indications among 168 consecutive patients. *Colectal Disease*. 2015;17 (7): 0155-060.
10. Yun HR, Chun H-K, Lee WS, Cho YB, Yun SH, Lee WY. Intra-operative measurement of surgical lengths of the rectum and the peritoneal reflection in Korean. *Journal of Korean medical science*. 2008; 23 (6): 999-1004.
11. Maslekar S, Pillinger SH, Monson JRT. Transanal endoscopic microsurgery for carcinoma of the rectum. *Surgical endoscopy*. 2007;21 (1): 97-102.
12. Palma P, Horisberger K, Joos A, Rothenhoefer S, Willeke F, Post S. Local excision of early rectal cancer: is transanal endoscopic microsurgery an alternative to radical surgery. *Rev Esp Enferm Dig*. 2009; 101(3): 172-8.
13. Darwood RJ, Wheeler JM, Borley NR. Transanal endoscopic microsurgery is a safe and reliable technique even for complex rectal lesions. *The British journal of surgery*. 2008; 95 (7): 915-8.
14. Marks JH, Frenkel JL, Greenleaf CE, D'Andrea AP. Transanal endoscopic microsurgery with entrance into the peritoneal cavity: is it safe? *Diseases of the colon and rectum*. 2014;57 (10): 1176-82.
15. Molina G, Bordeianou L, Shellito P, Sylla P. Transanal endoscopic resection with peritoneal entry: a word of caution. *Surgical endoscopy*. 2016; 30 (5): 1816-25.
16. Lee L, Burke JP, deBeche-Adams T, Nassif G, Martin-Perez B, Monson JR, et al. Transanal Minimally Invasive Surgery for Local Excision of Benign and Malignant Rectal Neoplasia: Outcomes From 200 Consecutive Cases With Midterm Follow Up. *Annals of surgery*. 2017.

Manuscript Information: Received: October 10, 2017; Accepted: January 29, 2018; Published: January 31, 2018

Authors Information: Islam H Metwally*; Osama Eldamshety

Surgical oncology unit, Oncology center Mansoura University (OCMU), Mansoura, Egypt

Citation: Metwally IH, Eldamshety O. Transanal endoscopic resection of high rectal lesions; should we extend our indications?. Open J Clin Med Case Rep. 2018; 1372.

Copy right statement: Content published in the journal follows Creative Commons Attribution License (<http://creativecommons.org/licenses/by/4.0>). © **Metwally IH 2018**

Journal: Open Journal of Clinical and Medical Case Reports is an international, open access, peer reviewed Journal focusing exclusively on case reports covering all areas of clinical & medical sciences.

Visit the journal website at www.jclinmedcasereports.com

For reprints and other information, contact editorial office at info@jclinmedcasereports.com