

Autologous hematopoietic stem cell transplantation in a patient with Hodgkin lymphoma on dialysis: Use of brentuximab vedotin as a bridge to transplant

Amanda P McIntyre; Jairam Krishnamurthy; Troy J Plumb; Philip J Bierman*

Philip J Bierman, MD

Department of Internal Medicine, Division of Oncology/Hematology, 987680 Nebraska Medical Center, Omaha, NE 68198, USA

Phone: 402-559-8500, Fax: 402-559-6520; Email: pjbierma@unmc.edu

Abstract

There is a high cure rate with initial treatment of Hodgkin lymphoma (HL), but for relapsed or refractory disease autologous hematopoietic stem cell transplantation (AHSCT) is the main stay of treatment. AHSCT is a challenge in patients with chronic kidney disease (CKD) due to the nephrotoxicity of the conditioning regimens, however there are reports of successful transplant in patients with multiple myeloma, mantle cell lymphoma, and amyloidosis-induced end stage renal disease (ESRD) requiring dialysis. We could not locate any reports of successful AHSCT in a patient with HL and ESRD requiring dialysis. We present the case of a patient with relapsed HL and ESRD requiring dialysis who was treated with brentuximab vedotin followed by a melphalan conditioning regimen and AHSCT who had long-term progression-free survival. Brentuximab vedotin, an anti-CD30 antibody, is widely used for relapsed and refractory HL and has been shown to improve the success rate of AHSCT. However, it is currently not advised for use in severe renal failure with only two reports of its use in patients with dialysis-dependent renal failure. This case is unique in two regards 1) the use of brentuximab vedotin in ESRD requiring dialysis and 2) successful AHSCT in a patient with relapsed HL and ESRD requiring dialysis.

Keywords

Hodgkin lymphoma; dialysis; relapsed Hodgkin lymphoma; brentuximab vedotin; hematopoietic stem cell transplant; ESRD

Abbreviations

HL: Hodgkin lymphoma; AHSCT: autologous hematopoietic stem cell transplantation; CKD: chronic kidney disease; ESRD: end stage renal disease

Introduction

In 2016, it is estimated that 8,500 people will be diagnosed with Hodgkin lymphoma (HL) in the United States and that 1,120 people will die from this disease [1]. There have been many advances in the treatment of HL with a relative 5-year survival of 86.2% [1]. Despite a high cure rate with initial treatment, a relapse rate of 10%-30% is still seen after achieving complete remission following primary

therapy [2]. The current standard of care for most patients with relapsed and refractory HL consists of conventional salvage therapy to reduce tumor burden, followed by high-dose chemotherapy and autologous hematopoietic stem cell transplantation (AHSCT) [2-4]. For patients treated with AHSCT for refractory or relapsed HL, long-term progression-free survival is seen in approximately 50% [5].

The use of AHSCT in patients with chronic kidney disease (CKD) presents additional challenges compared to those with preserved renal function due to the toxicity of the conditioning regimen [6]. However, there are multiple studies showing good outcomes and suggesting the feasibility of AHSCT in patients with CKD. Several reports have demonstrated that AHSCT can be successfully performed in patients with multiple myeloma and amyloidosis-induced renal failure requiring dialysis [7-15]. At least one report has also demonstrated a case of successful AHSCT in a dialysis-dependent patient with mantle cell lymphoma [16]. While AHSCT is the standard of care for relapsed/refractory HL, we could not find any reports of successful AHSCT in a HL patient on dialysis. We report a case of a patient with relapsed HL with end stage renal disease (ESRD) on dialysis who underwent AHSCT and had prolonged progression-free survival.

Case Report

The patient was a 46 year old male with a congenital absence of the left kidney, right renal dysplasia, and ESRD who started hemodialysis in 2000. He had a cadaveric renal transplant in November, 2001 with subsequent explant in March, 2003 due to graft failure. He was on hemodialysis ever since the explant in 2003. In 2007, he was diagnosed with stage III HL and completed six cycles of chemotherapy with ABVD (doxorubicin, bleomycin, vinblastine, and dacarbazine) resulting in complete remission. While being evaluated for another kidney transplant in July, 2011 he was found to have an abnormal positron emission tomography (PET) scan and a liver biopsy revealed recurrent classical Hodgkin lymphoma. The Reed Sternberg cells were positive for CD15 and CD30. He received three cycles of ChlVPP/ABV chemotherapy (chlorambucil, vinblastine, procarbazine, prednisone, doxorubicin, bleomycin, and vincristine) until October, 2011 when therapy was discontinued due to cytomegalovirus pneumonitis. A PET scan in November, 2011 showed marked improvement, but a subsequent PET scan in January, 2012 showed disease progression. He received brentuximab vedotin every three weeks for five doses. The first dose was 1.8 mg/kg and all subsequent doses were given at 1.4 mg/kg due to neuropathy. He had an excellent response to brentuximab vedotin (**Figures 1,2**). In June, 2012 he was treated with 140 mg/m² intravenous melphalan followed by AHSCT. He experienced peripheral neuropathy post-transplant and was hospitalized twice for respiratory failure of undetermined etiology requiring mechanical ventilation. A PET scan was performed in July, 2013 and remained negative for disease. He was followed without evidence of disease progression until his death in September, 2016 (51 months post-AHSCT) from complications related to chronic hemodialysis.

Discussion

Standard therapy for patients with relapsed or refractory HL is high-dose chemotherapy followed by AHSCT [2-4]. In addition to assessments of tumor sensitivity, evaluation of pre-transplant factors such as performance status and organ function are important due to the risks of morbidity and mortality following AHSCT. Deficits in pulmonary, hepatic, and renal function prior to transplant are associated with increased mortality due to the toxicity of the conditioning regimen [17].

One-year transplant-related mortality (TRM) for AHSCT for lymphomas is 4-8% in patients without renal failure [18]. Patients with renal failure undergoing AHSCT typically have higher transplant-related mortality (80-100% when dialysis is required according to one study) due to the toxic effects of conditioning regimens, which have a narrow therapeutic index even in patients with normal renal function [6]. It has been shown that patients with abnormal renal function prior to transplant are at increased risk for complications [19].

With several conditioning regimens for AHSCT in HL, the most common is BEAM (carmustine, etoposide, cytarabine, melphalan) [20]. Melphalan was chosen as the conditioning regimen for AHSCT in this case as it is the standard of care for patients undergoing AHSCT with multiple myeloma and amyloidosis-induced renal failure [21-22]. A pharmacokinetic and toxicity study performed by Tricot, et al. demonstrated that the presence of renal failure does not require a dose reduction of melphalan in autologous transplant for multiple myeloma, nor did it adversely affect post-transplant engraftment or overall survival [23]. However, a more recent study by El Fakih et al. showed a lack of clear survival benefit with higher dose melphalan (200 mg/kg) and potentially higher toxicities compared to lower doses of melphalan (<200 mg/kg) prior to AHSCT in dialysis-dependent myeloma patients [9]. In this case, 140 mg/m² melphalan was used as the conditioning regimen. We also chose melphalan as the conditioning agent due to reports of its success with AHSCT in patients with HL and normal renal function [24-26]. To our knowledge, there are no reports of HL treated with melphalan and AHSCT while on dialysis, and this information is not identified by the Center for International Blood and Marrow Transplant Research.

Another interesting aspect of this case is the use of brentuximab vedotin in renal failure. Hodgkin lymphoma (HL) is classically characterized by the presence of CD30-positive cells, termed Reed-Sternberg cells. Brentuximab vedotin is an anti-CD30 antibody conjugated to the anti-tubulin agent, monomethyl auristatin E (MMAE). Brentuximab vedotin has been used to target relapsed or refractory CD30-positive HL with overall response rates ranging from 50%-75% [27-29].

Brentuximab vedotin is currently approved for treatment of HL after failing AHSCT or after failure of at least two prior multi-agent chemotherapy regimens in patients who are not candidates for AHSCT [30]. Anderlini et al. recently showed exposure to brentuximab vedotin allowed more patients to reach allogeneic AHSCT in complete remission even with prior failed transplant [31]. In a large retrospective study on 240 patients with relapsed HL, Perrot et al. showed that of the 145 responders to brentuximab vedotin those who went on to AHSCT had a significantly longer median progression-free survival than those without transplant (18.8 vs. 8.7 months) [32].

Monomethyl auristatin E, the anti-tubulin component of brentuximab vedotin, is renally eliminated. It has been recently determined that severe renal impairment may cause decreases in antibody-drug conjugate exposure and increases in MMAE exposure [30]. Although the use of brentuximab vedotin is currently not advised for patients with severe renal failure (CrCl < 30 mL/min) due to increased toxicity, there are reports of its use in a patient with CD30-positive diffuse large B-cell lymphoma (DLBCL) with end-stage renal disease (ESRD) not requiring dialysis and as a first-line agent in a patient with advanced HL and acute renal failure requiring dialysis [33-34]. To our knowledge, there has been no report of the use of brentuximab vedotin in a patient with relapsed HL and ESRD requiring dialysis as a bridge to AHSCT.

Conclusion

AHSCT is accepted therapy for relapsed or refractory HL [2-4]. Although AHSCT in patients with renal failure presents additional challenges, this case shows that patients with relapsed or refractory HL should not necessarily be excluded from AHSCT because of the requirement for dialysis. Additionally, this report shows the use of brentuximab vedotin as initial therapy for relapsed disease followed by high-presence of ESRD requiring dialysis.

Figures

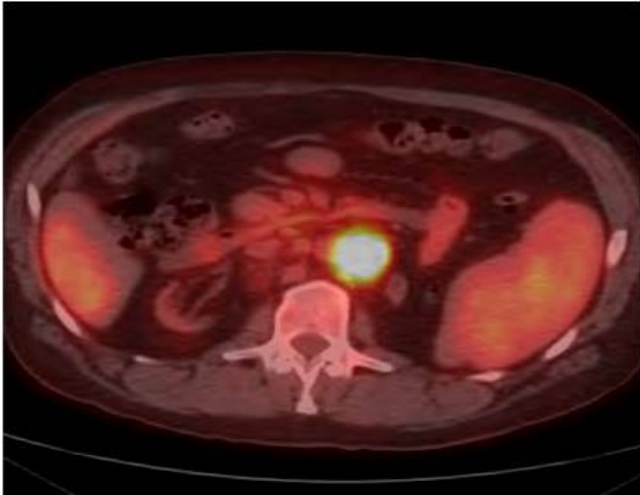


Figure 1: PET-CT from January 2012 (Deauville 5) showing a hypermetabolic retroperitoneal periaortic lymph node mass prior to initiation of brentuximabvedotin.

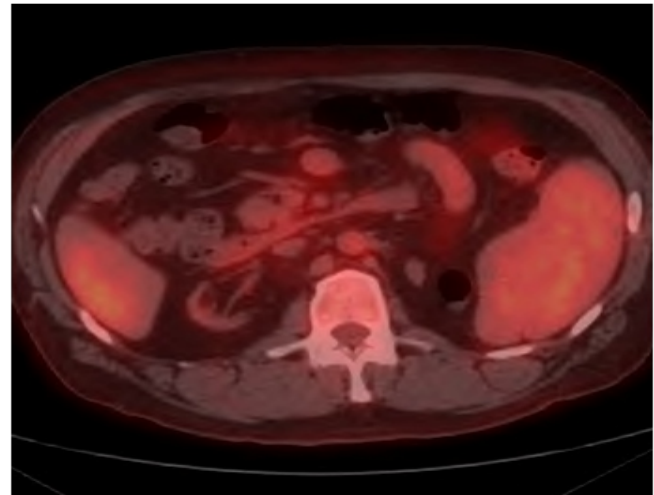


Figure 2: PET-CT from April 2012 (Deauville 3) showing a complete metabolic response after administration of brentuximabvedotin before ASCT.

References

1. SEER Cancer Statistics Review. National Cancer Institute; Accessed April 2016: 1975-2013.
2. Ansell SM. Hodgkin lymphoma: 2016 update on diagnosis, risk-stratification, and management. *Am J Hematol.* 2016; 91 (4): 434-442.
3. Linch DC, Winfield D, Goldstone AH, et al. Dose intensification with autologous bone-marrow transplantation in relapsed and resistant Hodgkin's disease: results of a BNLI randomised trial. *Lancet.* 1993; 341 (8852): 1051-1054.
4. Schmitz N, Pfistner B, Sextro M, et al. Aggressive conventional chemotherapy compared with high-dose chemotherapy with autologous haemopoietic stem-cell transplantation for relapsed chemosensitive Hodgkin's disease: a randomised trial. *Lancet.* 2002; 359 (9323): 2065-2071.
5. Sirohi B, Cunningham D, Powles R, et al. Long-term outcome of autologous stem-cell transplantation in relapsed or refractory Hodgkin's lymphoma. *Ann Oncol.* 2008; 19 (7): 1312-1319.
6. Heher EC, Spitzer TR. Hematopoietic stem cell transplantation in patients with chronic kidney disease. *Semin Nephrol.* 2010; 30 (6): 602-614.
7. Badros A, Barlogie B, Siegel E, et al. Results of autologous stem cell transplant in multiple myeloma patients with renal failure. *Br J Haematol.* 2001; 114 (4): 822-829.
8. Bird JM, Fuge R, Sirohi B, et al. The clinical outcome and toxicity of high-dose chemotherapy and autologous stem cell transplantation in patients with myeloma or amyloid and severe renal impairment: a British Society of Blood and Marrow Transplantation study. *Br J Haematol.* 2006; 134 (4): 385-390.

9. El Fakih R, Fox P, Popat U, et al. Autologous Hematopoietic Stem Cell Transplantation in Dialysis-Dependent Myeloma Patients. *Clin Lymphoma Myeloma*. 2015; 15 (8): 472-476.
10. Knudsen LM, Nielsen B, Gimsing P, Geisler C. Autologous stem cell transplantation in multiple myeloma: outcome in patients with renal failure. *Eur J Haematol*. 2005; 75 (1): 27-33.
11. Lee CK, Zangari M, Barlogie B, et al. Dialysis-dependent renal failure in patients with myeloma can be reversed by high-dose myeloablative therapy and autotransplant. *Bone Marrow Transplant*. 2004; 33 (8): 823-828.
12. Leung N, Kumar SK, Glavey SV, et al. The impact of dialysis on the survival of patients with immunoglobulin light chain (AL) amyloidosis undergoing autologous stem cell transplantation. *Nephrol Dial Transplant*. 2016; 31 (8): 1284-1289.
13. St Bernard R, Chodirker L, Masih-Khan E, et al. Efficacy, toxicity and mortality of autologous SCT in multiple myeloma patients with dialysis-dependent renal failure. *Bone Marrow Transplant*. 2015; 50 (1): 95-99.
14. Tosi P, Zamagni E, Ronconi S, et al. Safety of autologous hematopoietic stem cell transplantation in patients with multiple myeloma and chronic renal failure. *Leukemia*. 2000; 14 (7): 1310-1313.
15. Weinstein R, Kershaw G, Bailey J, et al. Safety and efficacy of autologous hemopoietic progenitor cell collection in tandem with hemodialysis in multiple myeloma with myeloma cast nephropathy. *J Clin Apher*. 2014; 29 (2): 83-89.
16. Tendas A, Cupelli L, Dentamaro T, et al. Feasibility of a dose-adjusted fludarabine-melphalan conditioning prior autologous stem cell transplantation in a dialysis-dependent patient with mantle cell lymphoma. *Ann Hematol*. 2009; 88 (3): 285-286.
17. Hamadani M, Craig M, Awan FT, Devine SM. How we approach patient evaluation for hematopoietic stem cell transplantation. *Bone Marrow Transplant*. 2010; 45 (8): 1259-1268.
18. Chen, Y, Lane, A, Logan B, et al. Impact of conditioning regimen on outcomes for patients with lymphoma undergoing high-dose therapy with autologous hematopoietic cell transplantation. *Biol Blood Marrow Transplant*. 2015; 21(6): 1046-1053.
19. Hahn T, Rondeau C, Shaukat A, et al. Acute renal failure requiring dialysis after allogeneic blood and marrow transplantation identifies very poor prognosis patients. *Bone Marrow Transplant*. 2003; 32 (4): 405-410.
20. Pearles M, Ceberio, I, Armand, P, et al. Role of cytotoxic therapy with hematopoietic cell transplantation in the treatment of Hodgkin lymphoma: Guidelines from the American Society for Blood and Marrow Transplantation: *Biol Blood Marrow Transplant*. 2015; 21 (6): 971-983.
21. Abidi MH, Agarwal R, Ayash L, et al. Melphalan 180 mg/m² can be safely administered as conditioning regimen before an autologous stem cell transplantation (ASCT) in multiple myeloma patients with creatinine clearance 60 mL/min/1.73 m² or lower with use of palifermin for cytoprotection: results of a phase I trial. *Biol Blood Marrow Transplant*. 2012; 18 (9): 1455-1461.
22. Tovar N, Cibeira MT, Rosinol L, et al. Bortezomib/dexamethasone followed by autologous stem cell transplantation as front line treatment for light-chain deposition disease. *Eur J Haematol*. 2012; 89 (4): 340-344.
23. Tricot G, Alberts DS, Johnson C, et al. Safety of autotransplants with high-dose melphalan in renal failure: a pharmacokinetic and toxicity study. *Clin Cancer Res*. 1996; 2 (6): 947-952.
24. Phillips GL, Meisenberg BR, Reece DE, et al. Activity of single-agent melphalan 220-300 mg/m² with amifostine cytoprotection and autologous hematopoietic stem cell support in non-Hodgkin and Hodgkin lymphoma. *Bone Marrow Transplant*. 2004; 33 (8): 781-787.
25. Russell JA, Selby PJ, Ruether BA, et al. Treatment of advanced Hodgkin's disease with high dose melphalan and autologous bone marrow transplantation. *Bone Marrow Transplant*. 1989; 4 (4): 25-429.

26. Stewart DA, Guo D, Sutherland JA, et al. Single-agent high-dose melphalan salvage therapy for Hodgkin's disease: cost, safety, and long-term efficacy. *Ann Oncol.* 1997; 8 (12): 1277-1279.
27. Younes A, Bartlett NL, Leonard JP, et al. Brentuximab vedotin (SGN-35) for relapsed CD30-positive lymphomas. *N Engl J Med.* 2010; 363 (19): 1812-1821.
28. Younes A, Bartlett NL, Leonard JP, et al. Brentuximab vedotin (SGN-35) for relapsed CD30-positive lymphomas. *N Engl J Med.* 2010; 363 (19): 1812-1821.
29. Younes A, Gopal AK, Smith SE, et al. Results of a pivotal phase II study of brentuximab vedotin for patients with relapsed or refractory Hodgkin's lymphoma. *J Clin Oncol.* 2012; 30 (18): 2183-2189.
30. Brentuximab vedotin, an antibody-drug conjugate, in patients with CD30-positive haematologic malignancies and hepatic or renal impairment. *Br J Clin Pharmacol.* Sep 2016;82 (3): 696-705.
31. Anderlini P, Saliba RM, Ledesma C, et al. Gemcitabine, Fludarabine, and Melphalan for Reduced-Intensity Conditioning and Allogeneic Stem Cell Transplantation for Relapsed and Refractory Hodgkin Lymphoma. *Biol Blood Marrow Transplant.* 2016; 22 (7): 1333-1337.
32. Perrot A, Monjanel H, Bouabdallah R, et al. Impact of post-brentuximab vedotin consolidation on relapsed/refractory CD30+ Hodgkin lymphomas: a large retrospective study on 240 patients enrolled in the French Named-Patient Program. *Haematologica.* 2016; 101 (4): 466-473.
33. Cao H, Yamamoto K, Yang LX, Weber R. Brentuximab vedotin: first-line agent for advanced Hodgkin lymphoma. *Anticancer Res.* 2013; 33 (9): 3879-3885.
34. Hill BT, Tubbs RR, Smith MR. Complete remission of CD30-positive diffuse large B-cell lymphoma in a patient with post-transplant lymphoproliferative disorder and end-stage renal disease treated with single-agent brentuximab vedotin. *Leuk Lymphoma.* 2015; 56 (5): 1552-1553.

Manuscript Information: Received: November 25, 2017; Accepted: January 23, 2018; Published: January 31, 2018

Authors Information: Amanda P McIntyre¹; Jairam Krishnamurthy²; Troy J Plumb³; Philip J Bierman^{2*}

¹College of Medicine, University of Nebraska, USA

²Department of Internal Medicine, Division of Oncology/Hematology, University Of Nebraska, USA

³Department of Internal Medicine, Division of Nephrology, University of Nebraska, USA

Citation: McIntyre AP, Krishnamurthy J, Plumb TJ, Bierman PJ. Autologous hematopoietic stem cell transplantation in a patient with Hodgkin lymphoma on dialysis: Use of brentuximabvedotin as a bridge to transplant. *Open J Clin Med Case Rep.* 2018; 1370.

Copy right statement: Content published in the journal follows Creative Commons Attribution License (<http://creativecommons.org/licenses/by/4.0>). © Bierman PJ 2018

Journal: Open Journal of Clinical and Medical Case Reports is an international, open access, peer reviewed Journal focusing exclusively on case reports covering all areas of clinical & medical sciences.

Visit the journal website at www.jclinmedcasereports.com

For reprints and other information, contact editorial office at info@jclinmedcasereports.com