

Periapical cyst associated with extra oral sinus tract

Cyril Pandarakalam, BDS, MDS*; Arthur Misischia, DMD

*Cyril Pandarakalam, BDS, MDS

Associate Professor, Section of Diagnostic Sciences, Department of Applied Dental Medicine, Southern Illinois University School of Dental Medicine, 2800 College Avenue, Alton, IL 62002

Phone: 618-474-7131; Email: cpandar@siue.edu

Description

A 33-year-old male presented with an extraoral draining fistula. Patient reported that 'a tree limb broke and fell on his chin, loosening all his lower incisor teeth, about a year ago'. Examination of the area revealed a draining fistula anteriorly on the chin (Figure 1). Intraorally, the lower incisors were mobile with heavy calculus and inflamed gingiva. CT scans, sagittal (Figure 2) and axial view (Figure 3) and panoramic radiograph (Figure 4) showed a well-defined radiolucency beneath the lower incisors thinning the lower border of the mandible. Our differential diagnosis included periapical cyst, periapical granuloma and traumatic bone cyst. Under local anesthesia, a full thickness mucoperiosteal flap was elevated and a cystic lesion was curetted out of the bony socket (Figure 5). The cystic lesion, 1.5 x 1.5 cm in size (Figure 6), sent for histopathologic examination and the report was periapical cyst (Figure 7). Periapical cyst is the most common odontogenic cyst and is usually associated by pulpal necrosis caused by caries or trauma.

Figures

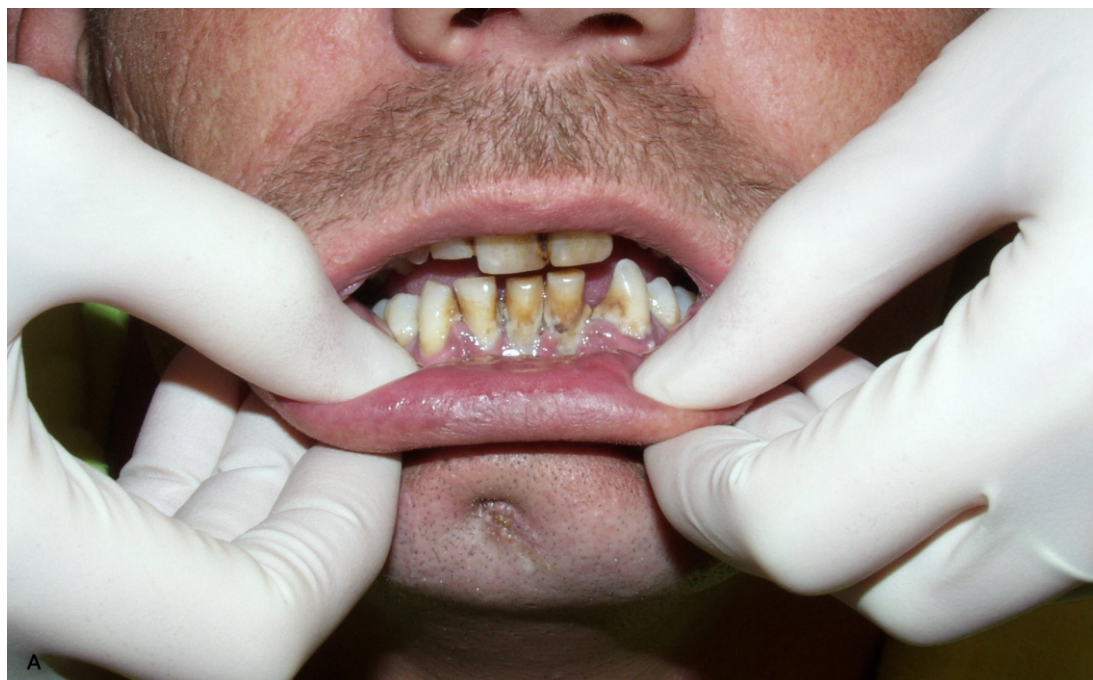

Figure 1

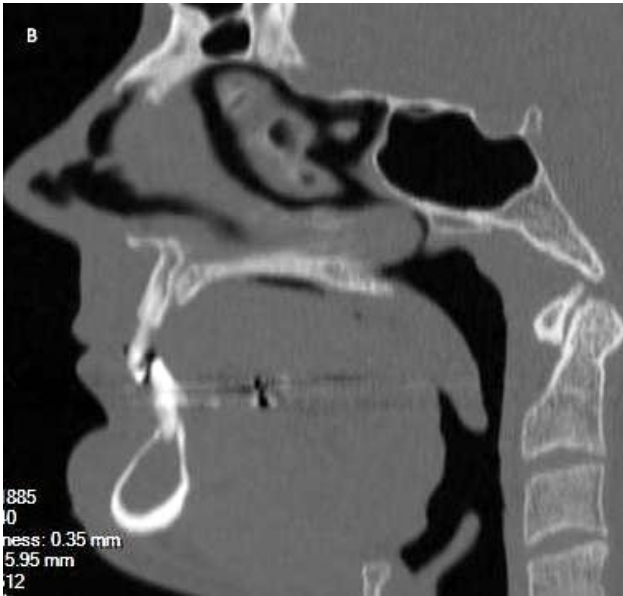

Figure 2

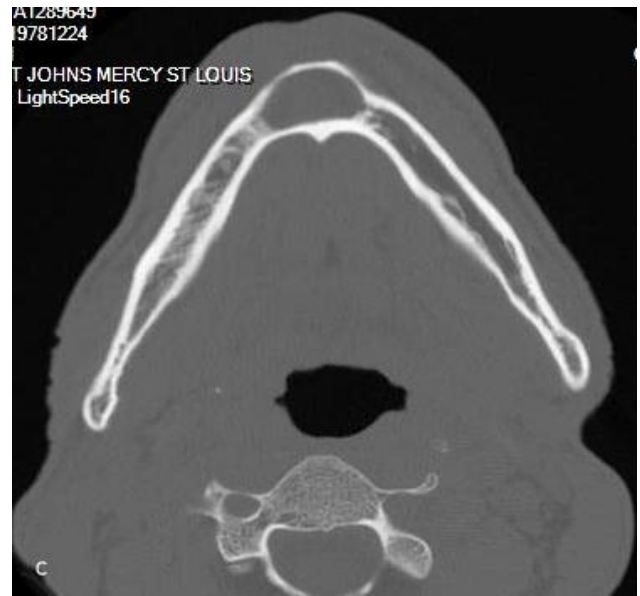

Figure 3

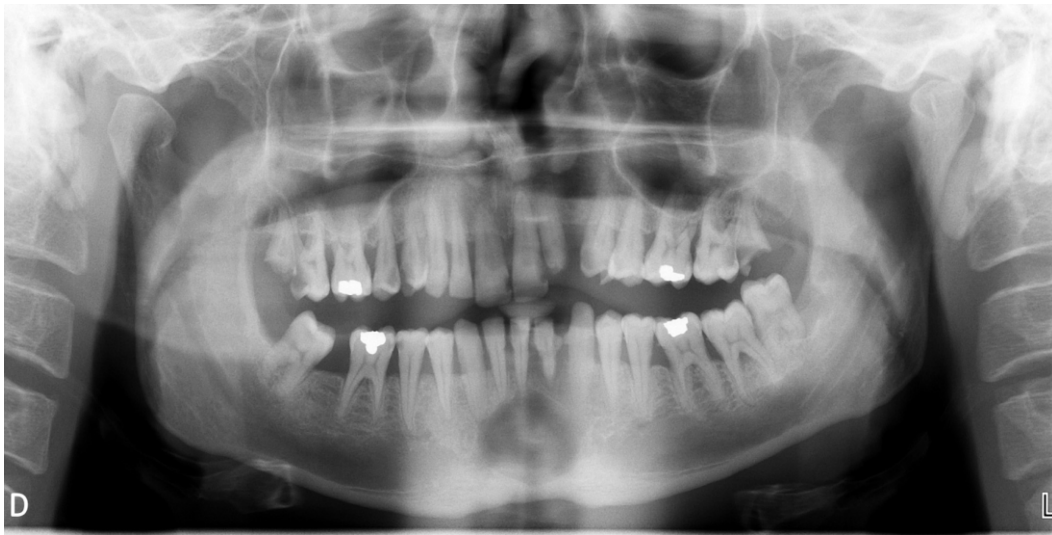

Figure 4

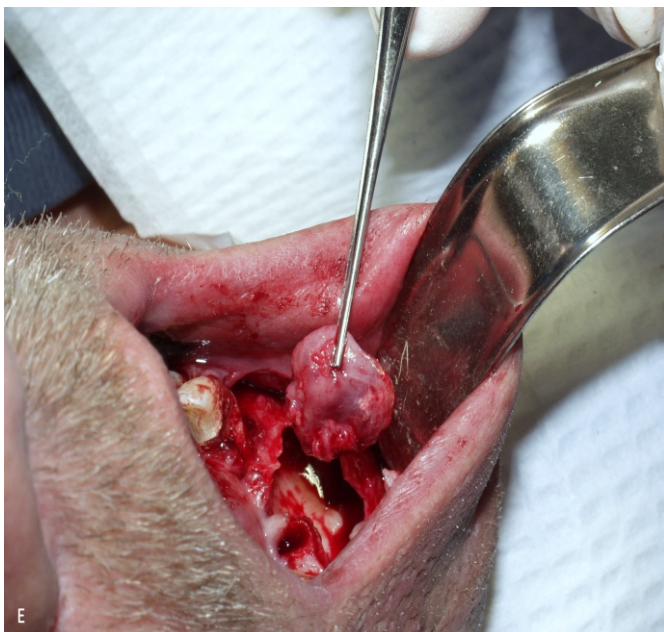

Figure 5

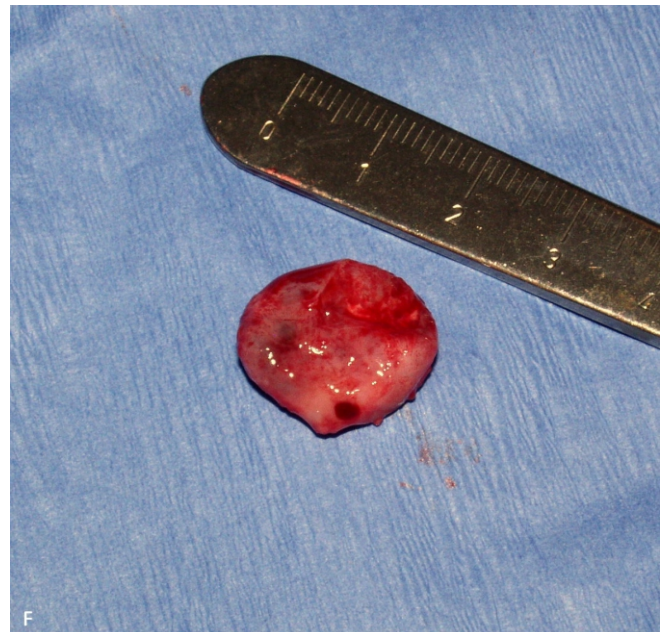


Figure 6

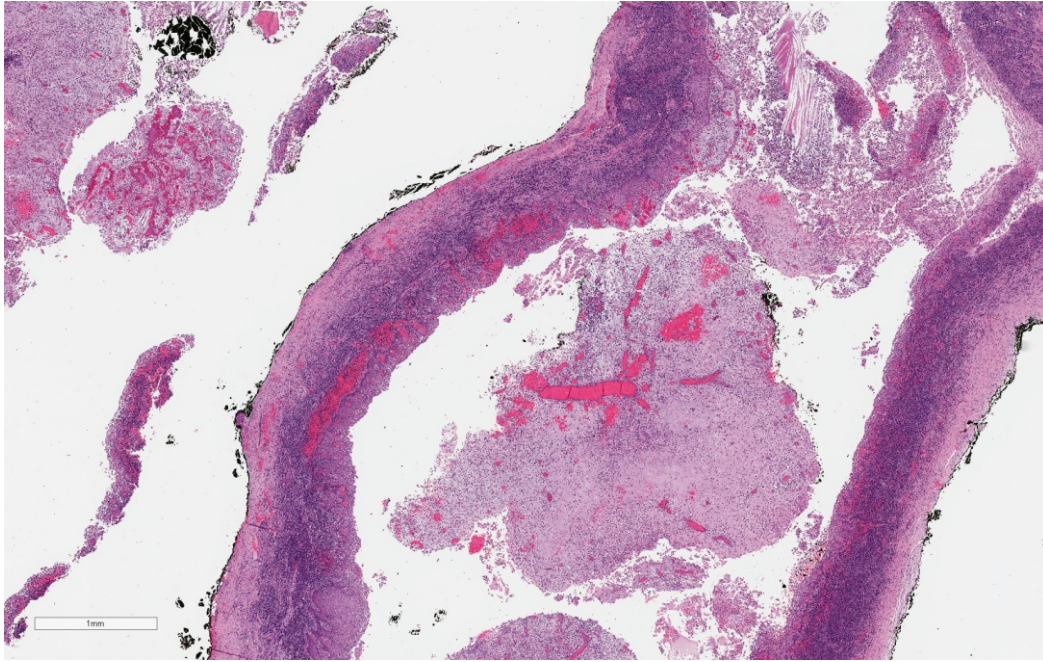


Figure 7

Acknowledgments

Mark Lingen DDS, PhD,

Professor of Pathology, The University of Chicago, USA

Manuscript Information: Received: October 27, 2017; Accepted: December 12, 2017; Published: December 28, 2017

Authors Information: Cyril Pandarakalam, BDS, MDS*; Arthur Misischia, DMD

Department of Applied Dental Medicine, Southern Illinois University School of Dental Medicine, 2800 College Avenue, Alton, IL 62002

Citation: Pandarakalam C, Misischia A. Periapical cyst associated with extra oral sinus tract. Open J Clin Med Case Rep. 2017; 1353.

Copy right statement: Content published in the journal follows Creative Commons Attribution License (<http://creativecommons.org/licenses/by/4.0>). © Pandarakalam C 2017

Journal: Open Journal of Clinical and Medical Case Reports is an international, open access, peer reviewed Journal focusing exclusively on case reports covering all areas of clinical & medical sciences.

Visit the journal website at www.jclinmedcasereports.com

For reprints and other information, contact editorial office at info@jclinmedcasereports.com