

Refractory antisynthetase syndrome controlled successfully with ongoing rituximab therapy

Matthew Jiang*; Christopher Fong

***Matthew Jiang**

Department of Rheumatology, Box Hill Hospital, Melbourne, Australia

Email: mjiang88@hotmail.com

Abstract

We present a case of refractory anti-synthetase syndrome with myositis and interstitial lung disease that progressed despite multiple immunosuppressive therapies. We were able to control the disease with repeated courses of rituximab, achieving a sustained clinical response and stabilisation of disease progression. There is limited evidence for the use of rituximab in this disease and this case demonstrates that ongoing treatment may be required to achieve sustained remission in severe refractory disease.

Keywords

rituximab; anti-synthetase; myositis

Abbreviations

ASS: anti-synthetase syndrome; CRP: C-reactive protein; ESR: erythrocyte sedimentation rate; CK: creatine kinase; HRCT: high resolution CT; MRI: magnetic resonance imaging; IVIg: intravenous immunoglobulin; FEV1: forced expiratory volume in one second; FVC: forced vital capacity; TLCO: diffusing capacity for carbon monoxide

Introduction

We present a case of a 40 year old woman with severe refractory myositis and interstitial lung disease secondary to anti-synthetase syndrome who achieved a sustained response to multiple courses of rituximab after relapsing on other immunosuppressive regimes.

Case Report

She initially presented in September 2013 with a several week history of progressive dyspnoea, fever, generalised myalgia and a proximal upper and lower limb rash. Initial investigations showed a C-reactive protein (CRP) of 54 mg/L (ref <5 mg/L) and erythrocyte sedimentation rate (ESR) of 64 mm/hr (ref 1 - 15 mm/hr). The initial creatine kinase (CK) was 3712 IU/L (ref 30 - 180 IU/L). Autoantibody screening showed a positive anti-nuclear antibody titre of 1:160, positive rheumatoid factor, positive SSA (Ro) antibody and positive Jo-1 antibody. This was consistent with a diagnosis of anti-synthetase syndrome.

Further workup included a high resolution computer tomography (HRCT) of her chest, which showed no evidence of pulmonary fibrosis. Magnetic resonance imaging (MRI) of hip did not

demonstrate myositis and a muscle biopsy of the thigh showed focal degenerative changes but no features consistent with anti-synthetase syndrome-related myositis.

She was started on high dose oral prednisolone (75mg daily) and in October 2013 she was treated with pulse methylprednisolone (1g daily for 3 days) followed by cyclophosphamide (1g every 4 weeks for 6 cycles). Oral prednisolone was recommenced at 75mg daily and slowly weaned.

During the 6 cycles of cyclophosphamide she had two flares of myositis managed with pulse methylprednisolone and was started on monthly intravenous immunoglobulin (IVIg) for 6 months. Azathioprine was also started at 25mg twice daily. She had another flare of myositis during the course of IVIg, which was managed with pulse methylprednisolone.

In April 2014, baseline respiratory function tests showed a restrictive defect with forced expiratory volume in 1 second (FEV1) of 58% predicted and forced vital capacity (FVC) of 63%. Diffusing capacity for carbon monoxide (TLCO) was reduced at 45%.

After another flare of myositis in October 2014, treated with methylprednisolone, we decided to treat with rituximab (1g at day 0 and day 14). Following rituximab, the CK improved but by January 2015 had started to increase again. During this time, azathioprine had been increased to a total daily dose of 250mg.

Between July 2015 and October 2015, she had another course of IVIg as well as methylprednisolone and cyclophosphamide due to refractory disease with the CK continuing to rise to 9629 despite treatment. Azathioprine was replaced with mycophenylate mofetil which was titrated up to 1.5g twice a day.

A repeat chest HRCT in October 2015 now showed established bilateral lower lobe interstitial fibrosis and ground glass opacities, consistent with a non-specific interstitial pneumonia (NSIP) pattern.

Monthly IVIg was commenced again however she required admission in January 2016 with a severe flare of myositis and a CK of 10,026. MRI of the thigh showed widespread myositis and a muscle biopsy was consistent with anti-synthetase syndrome-related myositis.

She was treated again with pulse methylprednisolone and further workup included an echocardiogram which demonstrated an increased pulmonary artery pressure of 49mmHg. Cardiac MRI was performed but did not show any myocarditis. Right heart catheterisation showed a pulmonary artery pressure of 34 mmHg and an elevated pulmonary capillary wedge pressure of 20mmHg. This was consistent with mild pulmonary hypertension secondary to left sided heart failure.

Given the severe refractory nature of her disease we decided to retreat with rituximab (2 doses) in Feb 2016. By this stage, she also had multiple sequelae of long term steroid use and was cushingoid in appearance. A subsequent course of rituximab was given 6 months later in August 2016 and she was followed up in clinic with ongoing clinical improvement and no further flares. Her prednisolone dose has been reduced down to 15mg daily. The most recent lung function tests from June 2016 showed an FEV1 of 62% predicted, FVC of 57% and TLCO of 50%, with no significant change from 2 years prior. Repeat HRCT in September 2016 did not show any progression of her fibrosis. She was last followed up in February 2017 with stable symptoms and is planned for ongoing rituximab.

Discussion

Anti-synthetase syndrome (ASS) was first described in 1990 by Marguerie et al [1] and characterised clinically by polymyositis/dermatomyositis, interstitial lung disease, arthritis and mechanic's hands [2]. Autoantibodies against anti-aminoacyl tRNA synthetase (aaRS) are a feature of this syndrome, with the most common being anti-Jo1 (directed against histidyl-tRNA synthetase) which is found in about 20-30% [3]. Interstitial lung disease is the most common complication, occurring in 70-89% of patients² and is the major determinant of morbidity and mortality [2-4].

Treatment of ASS usually involves high dose glucocorticoids [2,5] as first line. Other agents (e.g. azathioprine, methotrexate, mycophenylate mofetil, cyclophosphamide, intravenous immunoglobulin) have been used successfully in patients who fail to respond to steroids alone [2-4].

ASS often responds poorly to treatment and refractory ASS presents a management challenge given the rare nature of this syndrome and limited evidence to guide treatment. It is often described as intolerance or inadequate response to glucocorticoids and failure to respond to other immunosuppressive or immunomodulatory agents [2,4]. Rituximab has been shown to be effective in some patients with refractory ASS [2,4,6]. Common reasons for use of rituximab have included refractory myositis, refractory interstitial lung disease and/or refractory arthritis [7]. This has mostly been shown in case reports and series however there has been one open label, phase II trial⁴ which enrolled 10 patients, of which only 2 reached the primary endpoint (muscular improvement based on manual muscular testing). Secondary endpoints included normalisation in CK which showed an overall decrease from 399 IU/L (range, 48–11,718) to 74.5 IU/L (range, 40–47,857). In other studies, endpoints include improvement in lung function [3] and HRCT findings [2,6]. The effect on these endpoints has been variable, however the majority of patients demonstrate improvements in both respiratory function and HRCT findings.

Use of multiple courses of rituximab (up to 4 treatments) have been reported [7] in patients with refractory dermatomyositis/polymyositis with variable efficacy. Anti-synthetase antibodies appeared to be associated with the need for subsequent retreatment in this group.

In our patient, the main indication for rituximab was initially refractory myositis. Subsequent courses of rituximab were required due to ongoing refractory myositis and progressive interstitial lung disease. The main endpoints that we were able to measure include CK which improved after treatment. Respiratory function tests and HRCT findings both remained stable. We did not measure muscular improvement using manual muscular testing, however our patient had symptomatic improvement after treatment.

Our case adds to the current literature supporting the use of rituximab in the treatment of refractory anti-synthetase syndrome. It also suggests that ongoing treatment may be required in these patients to achieve a sustained response.

Figure

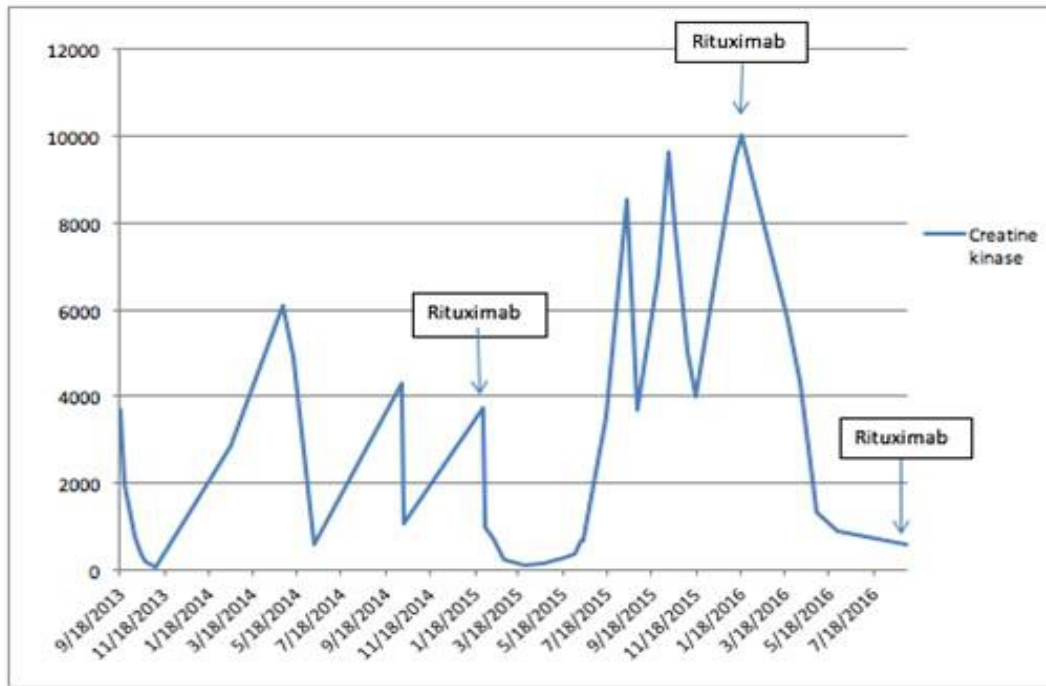


Figure 1: Trend in creatine kinase during treatment course

References

- Marguerie C, Bunn CC, Beynon HL, Bernstein RM, Hughes JM, So AK, et al. Polymyositis, pulmonary fibrosis and autoantibodies to aminoacyl-tRNA synthetase enzymes. *The Quarterly journal of medicine*. 1990; 77(282): 1019-38.
- Marie I, Dominique S, Janvresse A, Levesque H, Menard JF. Rituximab therapy for refractory interstitial lung disease related to antisynthetase syndrome. *Respiratory medicine*. 2012; 106(4): 581-7.
- Andersson H, Sem M, Lund MB, Aalokken TM, Gunther A, Walle-Hansen R, et al. Long-term experience with rituximab in anti-synthetase syndrome-related interstitial lung disease. *Rheumatology (Oxford, England)*. 2015; 54(8): 1420-8.
- Allenbach Y, Guiguet M, Rigolet A, Marie I, Hachulla E, Drouot L, et al. Efficacy of Rituximab in Refractory Inflammatory Myopathies Associated with Anti-Synthetase Auto-Antibodies: An Open-Label, Phase II Trial. *PLoS ONE*. 2015; 10(11).
- Nalotto L, Iaccarino L, Zen M, Gatto M, Borella E, Domenighetti M, et al. Rituximab in refractory idiopathic inflammatory myopathies and antisynthetase syndrome: personal experience and review of the literature. *Immunologic Research*. 2013; 56(2): 362-70.
- Sem M, Molberg Ø, Lund MB, Gran JT. Rituximab treatment of the anti-synthetase syndrome—a retrospective case series. *Rheumatology*. 2009; 48(8): 968-71.
- Unger L, Kampf S, Lüthke K, Aringer M. Rituximab therapy in patients with refractory dermatomyositis or polymyositis: differential effects in a real-life population. *Rheumatology*. 2014; 53(9): 1630-8..

Manuscript Information: Received: June 13, 2017; Accepted: September 01, 2017; Published: September 08, 2017

Authors Information: Matthew Jiang*; Christopher Fong

Department of Rheumatology, Eastern Health, Australia

Citation: Jiang M, Fong C. Refractory antisynthetase syndrome controlled successfully with ongoing rituximab therapy. Open J Clin Med Case Rep. 2017; 1307.

Copy right statement: Content published in the journal follows Creative Commons Attribution License (<http://creativecommons.org/licenses/by/4.0>). © **Jiang M 2017**

Journal: Open Journal of Clinical and Medical Case Reports is an international, open access, peer reviewed Journal focusing exclusively on case reports covering all areas of clinical & medical sciences.

Visit the journal website at www.jclinmedcasereports.com

For reprints and other information, contact editorial office at info@jclinmedcasereports.com