

Spontaneous bladder rupture in the setting of bladder diverticulum: A Case Report

Marang Makepe; Riteesh Bookun*

*Riteesh Bookun

Department of Vascular Surgery, Melbourne Health, Australia
Phone: 0090 409 0202; Email: riteesh.bookun@gmail.com

Abstract

Spontaneous bladder rupture is a rare and often neglected cause of sepsis or of an acute abdomen in the setting of lower urinary tract symptoms and acute renal impairment. Additionally, this case explores the challenges posed by concurrent psychiatric illness in the recognition of complications and the establishment of a diagnosis.

Keywords

bladder rupture; sepsis; urinary; acute abdomen

Case Report

A 56 year old obese man presented to a small outer metropolitan hospital with two days of abdominal pain, diarrhoea, fever, urinary frequency and abnormal behaviour. On examination, he was febrile and agitated with dry mucus membranes. He had left sided lower abdominal tenderness and haematuria. Fluid resuscitation and intravenous ceftriaxone were commenced. Due to the patient's background of attention deficit hyperactivity disorder (ADHD) and post-traumatic stress disorder (PTSD) for which he saw a private psychiatrist, the acute psychiatric team was consulted as the patient was distressed and agitated. The patient was then transferred to a larger hospital.

On presenting there, he was afebrile and hemodynamically stable. However his examination revealed a distended, guarded and tender abdomen. Inflammatory markers were raised (WCC $23.7 \times 10^9/L$, CRP 509.5 mg/L) and renal function was impaired (creatinine $176 \mu\text{mol/L}$, eGFR of $35 \text{ mL/min/1.73m}^2$) A CT scan of his abdomen showed features suggestive of emphysematous cystitis with a thickened urinary bladder and a 20 cm collection within the pelvis which was communicating with the bladder. This was thought to be secondary to a perforated bladder wall with extraperitoneal free air and a large diverticulum with emphysematous cystitic changes (Figures 1-5).

A laparotomy and diverticulotomy were performed the day after the original presentation. A large bladder diverticulum, grossly abnormal bladder mucosa and turbid fluid were encountered within the peritoneal cavity. The bladder was opened and repaired. Bilateral ureteric stents, a drain and a urinary catheter were inserted. The patient was admitted to the Intensive Care Unit postoperatively. Histologic results from the diverticulum showed acutely inflamed tissue with fat necrosis, scattered reactive fibroblasts and no evidence of malignancy.

The patient remained in intensive care until the 4th post-operative day when he was extubated successfully following cessation of ionotropic support. He subsequently began tolerating diet and opening his bowels. The laparotomy wound partially dehisced. This was managed with daily packing dressing. Piperacillin / Tazobactam that was started intra-operatively was de-escalated to amoxicillin / clavulanate day 7 post-op after a urine culture taken on presentation grew enterococcus faecium. On the 9th post-operative day 9, the surgical drain was removed. In the immediate post-operative period, deranged liver functions were noted and monitored. These were investigated with an abdominal ultrasound that showed fatty infiltration of the liver and mild right sided hydronephrosis. Liver function markers returned to normal limits on cessation of hepatotoxic medications.

Following the removal of the surgical drain the patient started to have low grade temperatures and diaphoresis. He complained of penile tip pain. His examination was repeatedly unremarkable apart from crackles which were heard on auscultation at the right lung base. Repeated septic screens were negative apart from an elevated CRP of 159 and a wound swab from the laparotomy wound that grew gram positive cocci. Piperacillin / Tazobactam was recommenced and the fevers settled after 3 days. The abdominal wall sutures and staples were removed on the 11th post-operative day. Clinically, the patient steadily improved and a cystogram was planned.

From day 11, nursing staff reported that the patient was having abnormal and bizarre behaviours that would occur overnight. It was noted at this stage that the patient had not been on his regular dexamphetamine dose that he was prescribed for management of ADHD. His psychiatrist was consulted and recommended recommencing his dexamphetamine to assist in the control of his behaviours.

The patient grew increasingly agitated, disruptive and difficult to manage on the ward. Dexamphetamine was ceased and the patient was managed with chemical and mechanical restraints. Several days later he was noted to be obtunded and to have localized peritonism in the right iliac fossa. His renal function had acutely deteriorated. A CT scan of his abdomen demonstrated a malpositioned right ureteric stent in the mid ureter and persistent hydronephrosis and a thick-walled 6.0 x 6.6 x 7.5cm thick-walled fluid collection, to the right lateral aspect of the bladder, consistent with a bladder diverticulum or a paravesical collection. A subsequent CT cystogram demonstrated a trabeculated urinary bladder with reflux of contrast into the ureters and renal pelvicaliceal system bilaterally with no contrast flow into the collection or diverticulum. A right sided nephrostomy and CT guided drainage of the collection were performed and the patient was re-admitted to the intensive care unit.

During his second ICU admission the patient did not require any ionotropic support. Meropenem and vancomycin were commenced empirically, followed by a change to Piperacillin / Tazobactam. A septic screen was repeated. Cultures taken from the abdominal drain, right nephrostomy, urinary catheter and blood were all negative. A swab of the surgical wound grew gram positive cocci. The patient returned to the ward on day 19.

The patient returned to theatre for removal of bilateral stents, as the right was malpositioned. A nephrostogram showed a long segment stricture in the distal third of the ureter with contrast able to pass into the bladder after significant delay.

On day 28, a repeat CT KUB was performed to reassess the abdominal collection. This showed a

marked improvement of the right paravesical collection with only a small amount of fluid within it. Following repeat negative drain and urine cultures, both the abdominal drain and urinary catheter were removed. A renal MAG 3 scan, performed thereafter, showed a normal left kidney and a poorly functioning small right kidney with delayed excretion of tracer with a delayed half clearance time of 20 minutes. The left kidney contributed to 84.3% of total function and right kidney, 15.7%.

Just over a month into the admission the patient again started developing fevers. These were associated with chills, rigors, diaphoresis and confusion overnight. Clinical examination was unremarkable apart from right sided basal crepitation on auscultation of the chest. Septic screen showed raised inflammatory markers, 3 negative blood cultures, a left sided small pleural effusion on chest x-ray and a pseudomonas species in the urine cultures. A repeat CT scan of the abdomen showed a re-accumulation of the previous right paravesical collection, which was drained under radiological guidance. Cultures from the drain grew pseudomonas. Intravenous ceftazadime was given for 2 weeks after consultation with the Infectious Diseases unit.

Following discussion of the case at a multi-disciplinary team meeting, the patient underwent a rigid cystoscopy and a right retrograde pyelogram. This showed no stricture or extravasation of contrast. The right nephrostomy and abdominal drain were removed several days later. Repeat urine cultures showed no growth and ceftazidime was ceased. The patient remained hemodynamically stable and was discharged to respite care for Urology follow-up 2 months later.

Discussion

The aetiology of bladder rupture can be divided into traumatic, iatrogenic, idiopathic and spontaneous causes. External trauma is by far the most common cause, comprising of 82% of all bladder ruptures, followed by iatrogenic injury at 14%. Rarer causes of bladder rupture include intoxication at 2.9% and spontaneous rupture at <1%. Idiopathic bladder trauma occurs in patients who consume large quantities of alcohol or consume large amounts of fluid. Previous bladder surgery is also a risk factor as areas of scar formation are weak and prone to disruption. Bladder rupture in these cases is caused by bladder distension coupled with minor external trauma, such as a minor fall. Spontaneous bladder rupture is a rare cause of an acute abdomen and may be overlooked in the acute setting, thus delaying diagnosis and definitive management. It can be caused by over-distension secondary to urinary retention such as urethral obstruction secondary to a gravid or fibroid uterus, tabes dorsalis or post-operative retention. Risk factors include cystitis, urethral rupture, alcoholic intoxication, previous bladder surgery, congenital bladder abnormalities and previous radiation therapy. Ruptures can be either extraperitoneal or intraperitoneal, or a combination of both.

The presentation of bladder rupture is non specific. Patients can present with gross haematuria, suprapubic pain and tenderness as well as lower urinary tract symptoms. Gross haematuria is common but its absence does not exclude bladder rupture. Progressive abdominal distension can occur secondary to urinary ascites. Laboratory studies such as serum creatinine are useful but non diagnostic in the setting of bladder rupture. Increased concentrations of creatinine can be found in the peritoneal fluid if sampled. Cross-sectional imaging with computed tomography (CT) particularly CT cystography is useful for assessing extravasation of urine.

The patient in this case had several risk factors including a lower urinary tract infection, a bladder diverticulum, which may have been congenital or due to chronic outlet obstruction, as well as the use of psychotropic agent dexamphetamine. Bladder diverticuli are herniations of the urothelium of the bladder, through the muscularis and weak points, where perforation can occur. He presented with an acute abdomen and haematuria, which gave clues to a genitourinary aetiology but were non-specific. Diagnosis was delayed because of delay to cross-sectional imaging and also because a psychiatric component was thought plausible, rather than an acute delirium in the setting of sepsis. Given that the patient had intraperitoneal bladder rupture with sepsis, surgical management was required [1,2].

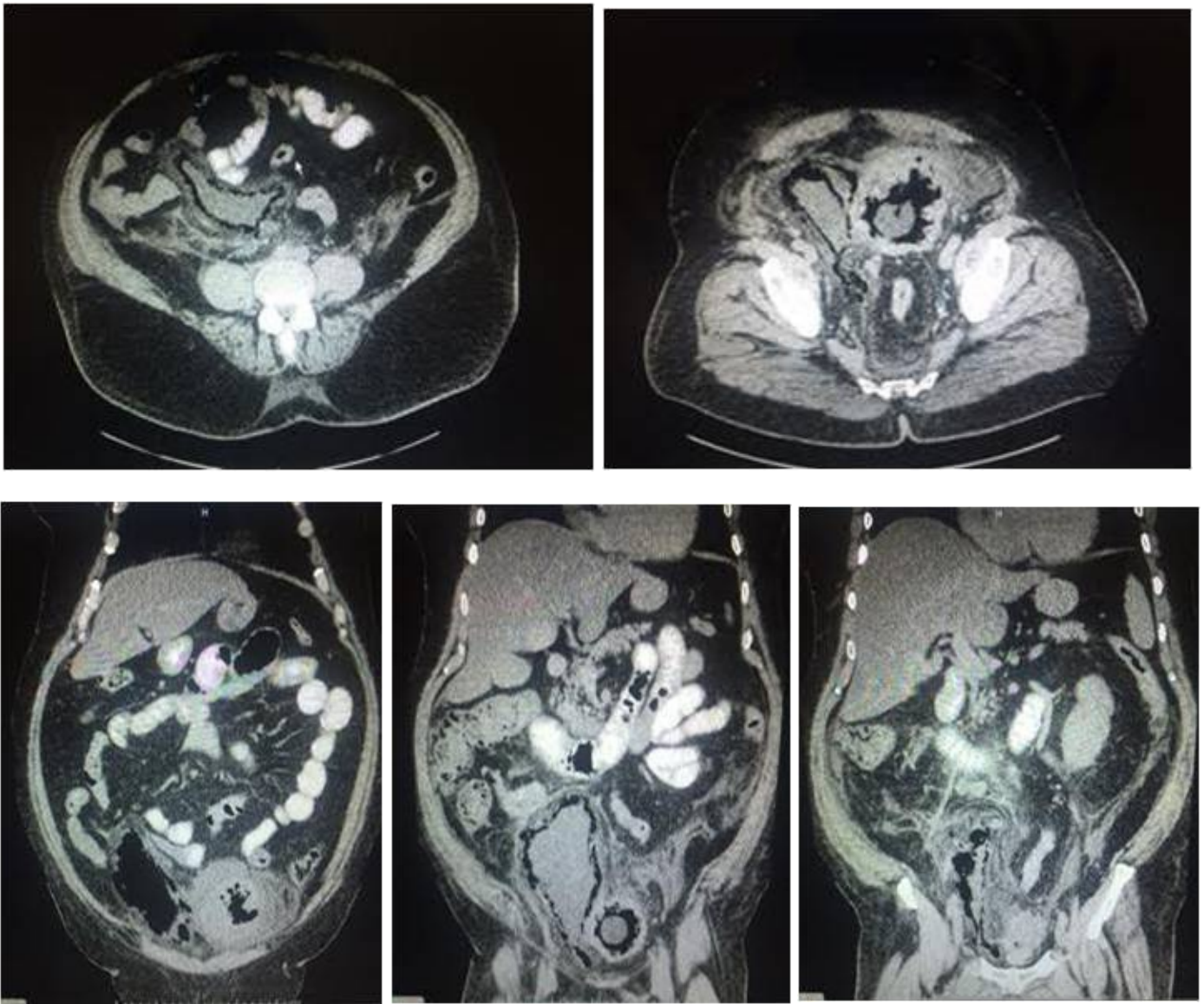
Following the definitive surgical management, there was a long recovery. The patient developed complications from the surgery which included wound dehiscence, abdominal abscess as well as ureteric obstruction secondary to malposition of the ureteric stent. Common complications in bladder surgery include persistent or recurrent urinary extravasation, wound dehiscence, haemorrhage, pelvic abscess, intra-abdominal infection, urinary tract infection, lower bladder capacity and urinary urgency. Even in the presence of robust bladder reconstruction, urinary extravasation can still occur through the closure. It is therefore important to keep the bladder decompressed with a urinary catheter for some time after the repair [3,4].

A major contributor to the patient's acute presentation and post-operative complications was the use of dexamphetamine, which the patient had used for some time for treatment of ADHD. Dexamphetamine is a non-catecholamine, sympathomimetic amine with central nervous system stimulant activity. It stimulates both α and β -adrenergic receptors. The bladder neck has a large number of α receptors. Stimulation of these receptors increases bladder outlet resistance through contraction of the bladder neck. When ceased suddenly, patients can experience withdrawal effects that include irritability, extreme fatigue, hyperactivity and personality changes. Chronic intoxication can cause psychosis which is often indistinguishable from schizophrenia. Dexamphetamine can also cause, through its stimulant effects, increased mental alertness and euphoria which can manifest in behavioral changes and psychosis. In this case, the patient likely had chronic outlet obstruction which predisposed him to development or worsening of a bladder diverticulum as well as cystitis, which are risk factors of rupture. Following his surgical management of the bladder rupture, recommencement of the dexamphetamine not only increased the bladder outlet obstruction, which could have contributed to the re-accumulation of the paravesical collection, but also delay in the diagnosis of the collection.

Conclusion

Spontaneous bladder rupture is a rare clinical condition and that can cause significant morbidity and in some cases mortality. As the presentation and most investigations can be non-specific, a high index of suspicion should be kept, particularly in the context of risk factors and genitourinary symptoms. This case also highlights how psychiatric illness and psychotropic medication can cloud the clinical picture.

Figures



Figures: 1-5

References

1. Al-Aghbari, S., Al-Harthy, A., Al-Reesi, A., Al-Wahaibi, K., & Al-Qadhi, H. (2011, November). Laparoscopic repair of traumatic intraperitoneal bladder rupture. *Sultan Qaboos Univ Med J*, 11(4), 515-8.
2. Kim, F. (2008, Sept). Laparoscopic management of intraperitoneal bladder rupture secondary to blunt abdominal trauma using intra corporeal single layer suturing technique. *Int Braz J Urol*, 34(5), 650.
3. Sagalowsky, A., & Peters, P. (1998). Genitourinary Trauma. In P. W. al, & P. Walsh (Ed.), *Campbell's Urology* (7th ed., pp. 3104-8). Philadelphia, Pa, USA: WBS.
4. Srinivasa, R., Akbar, S., Jafri, S., & Howells, G. (2016, Jan). Genitourinary Traum: A Pictorial Essay. *Emerg Radiol*, 16(1), 21-33.

Manuscript Information: Received: April 17, 2017; Accepted: July 07, 2017; Published: July 10, 2017

Authors Information: Marang Makepe¹; Riteesh Bookun²

¹Department of General Surgery, Austin Health, Australia

²Department of Vascular Surgery, Melbourne Health, Australia

Citation: Makepe M., Bookun R. Spontaneous bladder rupture in the setting of bladder diverticulum: A Case Report. Open J Clin Med Case Rep. 2017; 1287

Copy right statement: Content published in the journal follows Creative Commons Attribution License (<http://creativecommons.org/licenses/by/4.0>). © **Bookun R 2017**

Journal: Open Journal of Clinical and Medical Case Reports is an international, open access, peer reviewed Journal focusing exclusively on case reports covering all areas of clinical & medical sciences.

Visit the journal website at <http://jclinmedcasereports.com>

For reprints and other information, contact editorial office at info@jclinmedcasereports.com