

Hepatocellular carcinoma in an adolescent with Hepatitis B and E-Antigen seroconversion

Emily C Hon, MD; Kimberly P Newton, MD; Hyunah Ahn, MD; Denise Malicki, MD, PhD; Jeannie S Huang, MD, MPH*

*Jeannie S. Huang, MD, MPH

Division of Pediatric Gastroenterology, Rady Children's Hospital and University of California San Diego, 9500 Gilman Drive, La Jolla, CA 92093

Phone: (858) 966 4003; Email: jshuang@ucsd.edu

Abstract

We report the case of an adolescent Korean male with chronic hepatitis B virus (HBV) infection and hepatocellular carcinoma (HCC). At the time of presentation, the patient had metastatic HCC disease. Failure to meet treatment guidelines, inadequate disease monitoring, as well as social barriers to medical follow-up contributed to suboptimal disease management. We review each of these issues in this report and discuss potential solutions.

Keywords

hepatitis B; liver disease; hepatocellular carcinoma; pediatrics

Abbreviations

AFP: Alpha-fetoprotein; ALT: Alanine aminotransferase; ER: Emergency Room; HBeAb: Hepatitis B E Antibody; HBeAg: Hepatitis B E Antigen; HBsAb: Hepatitis B Surface Antibody; HBsAg: Hepatitis B Surface Antigen; HBV: Hepatitis B Virus; HBV DNA PCR: Hepatitis B Virus Deoxyribose Nucleic Acid Polymerase Chain Reaction; HCC: Hepatocellular Carcinoma; IFN-alpha: Interferon-alpha; ULN: Upper limit of normal

Introduction

There are 400 million people worldwide with chronic Hepatitis B virus (HBV) infection [1]. The risk of developing chronic HBV infection is inversely related to age at acquisition; 90% of neonates will develop chronic infection, versus 25-30% of infants, and <5% of healthy adults [2]. Complications from chronic HBV infection are fortunately rare but devastating. These include cirrhosis, liver failure, and hepatocellular carcinoma (HCC).

Although one-third of all chronic HBV infections are in children [3], most children are clinically well. Suboptimal risk-benefit ratios and limited efficacy of available treatment options commonly lead to a wait-and-see approach. Treatment is currently recommended for patients with both persistent HBV infection and liver inflammation, as defined by HBV viremia and elevated liver transaminase thresholds. However, many patients do not meet treatment criteria. As a result, many chronic HBV-infected youth are generally followed without treatment during childhood and adolescence. Nevertheless, ongoing

monitoring on a quarterly basis to detect disease activity and complications is important and the mainstay of HBV medical management in children.

We report the case of a previously healthy adolescent with chronic HBV infection, who did not meet criteria for anti-viral treatment, did not follow monitoring guidelines, and presented with metastatic HCC.

Case Report

A 15-year-old Korean male, with a reported history of perinatal HBV infection presented to a local emergency room (ER) following a syncopal episode after swimming. Before the syncopal episode, he experienced 2 weeks of generalized, intermittent, crampy abdominal pain but otherwise no stigmata of chronic liver disease. He had not been monitored by a primary caregiver or pediatric specialist for his history of HBV infection and had never received antiviral therapy. In the ER, he was hypotensive with blood pressure of 76/41mmHg and anemic with hemoglobin of 11.6 g/dl. Admission labs were significant for alanine aminotransferase (ALT) 27 U/L, gamma-glutamyl transferase 59 U/L. His prothrombin time-international normalized ratio was 1.1. He was hepatitis B surface antigen (HBsAg) positive, hepatitis B surface antibody (HBsAb) negative, hepatitis B e Antigen (HBeAg) negative, and hepatitis B e antibody (HBe Ab) positive; other viral hepatitis and human immunodeficiency virus serologies were negative. HBV deoxyribonucleic acid (DNA) was relatively low at 7,776 IU/ml. Alpha-fetoprotein (AFP) was elevated to 110,000 ng/ml. An abdominal computed tomography [4] scan demonstrated an 11 x 6.7 cm² mass at the left lateral segment of his liver with active bleeding and hemoperitoneum. Bone scan, head and chest CT were negative for metastases. At abdominal exploration, a ruptured left hepatic lobe mass with metastatic deposits (stage IIIB disease) at the left diaphragm and mesentery was discovered. Histopathology was consistent with a moderately differentiated HCC with positive surgical margins (Figures 1 and 2).

Treatment with entecavir was initiated with subsequent HBV DNA PCR <357 IU/ml, AFP 2364 ng/ml, and ALT 29U/L after 2 weeks of therapy. Sorafenib was started 1 month after tumor resection. Soon after, the patient moved to Korea with referral to a local oncologist. Sorafenib was discontinued by the family without medical consultation. Subsequent radiologic follow-up one month later demonstrated lung metastases, and the patient has been lost to our follow-up.

Discussion

We present a case of metastatic hepatocellular carcinoma in a 15-year-old male with lack of follow-up for known chronic HBV infection resulting from perinatal exposure. Below, we discuss the salient issues regarding this patient.

Current treatment options for chronic HBV infection in the pediatric population are limited. Guidelines restrict initiation of treatment to patients meeting strict criteria (HBV DNA levels greater than or equal to 20,000 IU/ml, ALT greater than two times the upper limits of normal (ULN), and liver pathology with moderate to severe active inflammation [5]), and therapeutic options are currently limited to five drug regimens in children [6]. Interferon-alpha (IFN-alpha) is the most effective (30% HBeAg seroconversion, 10% HBsAg seroconversion), but only when limited to HBeAg-positive patients with serum ALT greater than two times the ULN [7]. In addition, IFN-alpha requires subcutaneous

injection. Lamivudine is a safe and effective oral medication, but has 64% risk of developing drug-resistant mutations after 3 years of treatment [2] and has lower HBsAg seroconversion (2-3%) [7]. Adefovir has lower seroconversion rates [2] than IFN-alpha or lamivudine and increasing drug resistance over time [8]. Entecavir has comparable seroconversion rates with lamivudine, very low rates of drug-resistance in nucleoside-naïve patients [9], low rates of reactivation in setting of chemotherapy or immunosuppression [10] and has been FDA-approved for patients greater than 16 years of age [8]. Tenofovir has been FDA-approved for patients greater than 12 years and has been shown to lead to higher rates of ALT normalization and HBV DNA suppression but without statistically significant effects on HBeAg clearance or loss [11]. In the case presented, our patient did not satisfy the strict treatment criteria for HBV; however, the decision was made to begin treatment with entecavir and ultimately sorafenib, an oral multikinase inhibitor that has been shown to prolong median survival by 3 months in adults with HCC [12], off-label given his advanced disease at presentation.

Children account for 1/3 of the population affected by chronic HBV infection. Similar to our patient, young patients with chronic HBV infection commonly do not meet treatment criteria, as their ALT is often normal when HBV DNA is elevated during a prolonged immune tolerant phase. However, patients with chronic HBV infection acquired *perinatally* (as in the case of our patient) can demonstrate a more aggressive progression of disease and a higher risk for developing HCC as compared to patients infected in adulthood [5]. In addition, our patient was male and the prevalence of HCC is greater among males than females with a male: female ratio of 11:5 [13]. Our case highlights a potential need for different guidelines for treatment initiation particularly in regards to addressing HBV complication and HCC development risk. Only recently have studies in viral hepatitis treatment begun to focus on disease complication outcomes. Currently, there appears to be strong evidence that antiviral therapy is effective in reducing HCC development in adult patients with HBV and cirrhosis; however, further studies are needed to determine whether long-term antiviral therapy in the absence of cirrhosis (the usual finding in the majority of the pediatric population with chronic hepatitis B infection) is effective in reducing HCC development [14,15]. Even when treatments are efficacious in reducing HCC development in adults, such treatments do not eliminate the risk for HCC [16]. Long-term, well-controlled studies are needed in children.

In the case presented, it is possible that metastatic HCC could have been prevented with earlier antiviral treatment or if screening methods such as annual abdominal sonograms and AFP measurements had been performed for early detection and therapy. In most pediatric HBV cases, the pediatrician will be the first healthcare professional aware of a patient's chronic HBV infection. However, recent findings by the Institute of Medicine cite poor provider knowledge regarding HBV screening, transmission, serologic testing, and management as a major factor impeding chronic hepatitis B prevention and control [17]. A recent *Pediatrics* article [8] establishes guidelines for pediatricians regarding whom to screen, which studies to obtain for an HBsAg-positive patient, and when to refer to a specialist, but the guidelines become less specific beyond that. Nevertheless, data demonstrate that 65% of HBV infected Americans are unaware of their HBV status, rates of screening remain suboptimal (<20%), and only 40% of those identified with chronic HBV are linked to care [18]. Given the complex nature of HBV, poor provider knowledge [17], evolving chronic HBV management guidelines, and potentially devastating outcome of these patients, it may be prudent for chronic HBV patients, once

identified, to be followed by a pediatric liver subspecialist.

Finally, several social barriers to patient care must be acknowledged. These include poor public knowledge of HBV [17], language and cultural barriers, distrust of western healthcare, and general lack of healthcare among Asians [19,20]. One study at an urban Korean university cited confusion, misunderstanding, and concerns for stigma as reasons Koreans did not seek medical help for their HBV status [21]. These findings may explain why our patient with known perinatal HBV infection did not pursue follow-up for his condition. Increased efforts are needed to reduce these barriers.

Conclusion

In summary, we report the case of an Asian adolescent male with suboptimal medical surveillance for his perinatal HBV infection who presented with subsequent metastatic HCC. Improved methods of screening, monitoring, and perhaps better treatment options for chronic HBV are needed to prevent such morbid outcomes. Increasing public awareness of this disease as well as provider awareness of chronic HBV screening with referral of patients to a pediatric hepatologist may help to reduce morbidity and mortality among affected children.

Figures

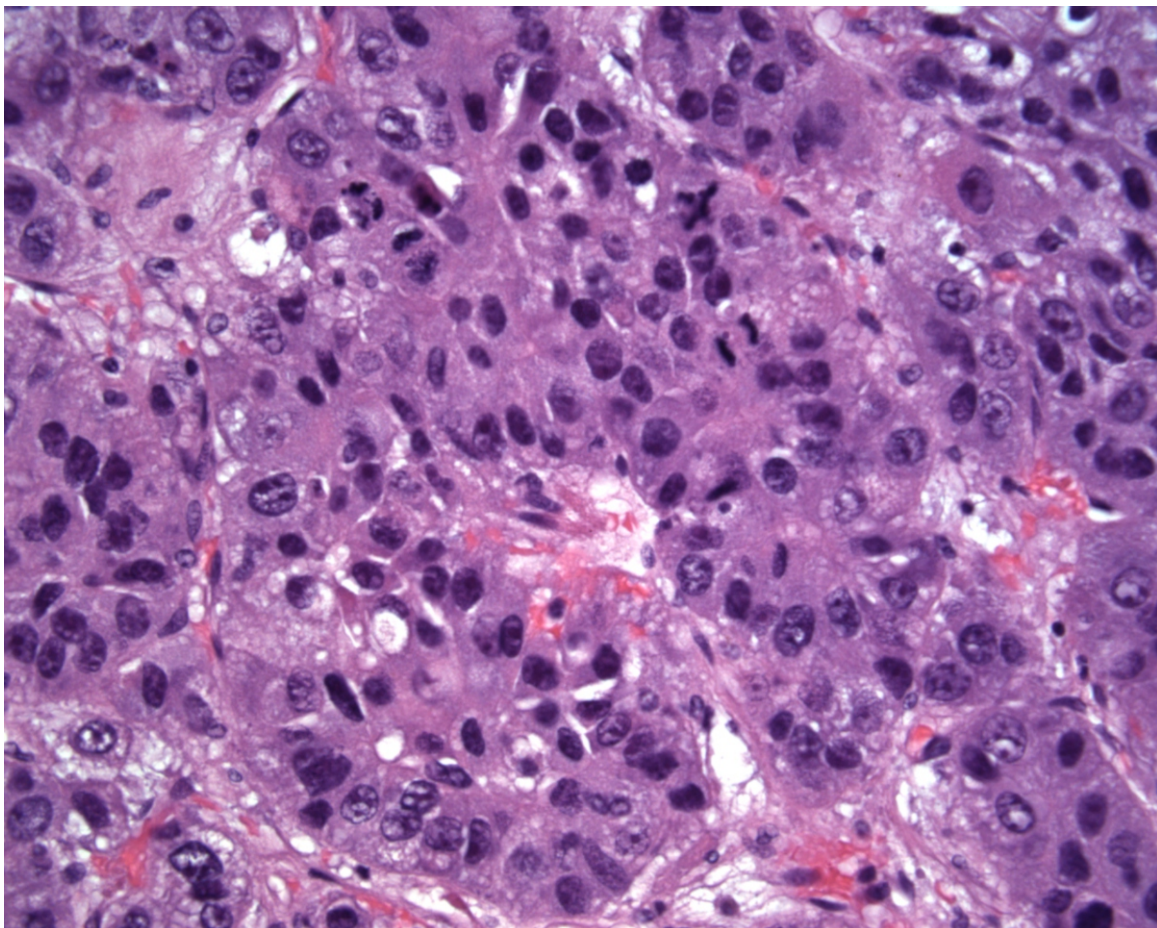


Figure 1: H&E (400x): Sections showed moderately to well-differentiated neoplastic hepatocytes in cords and thick trabeculae, with cellular pleomorphism, prominent nucleoli, and brisk mitotic activity. Areas of tumor showed necrosis and hemorrhage, and there was lymphovascular invasion.

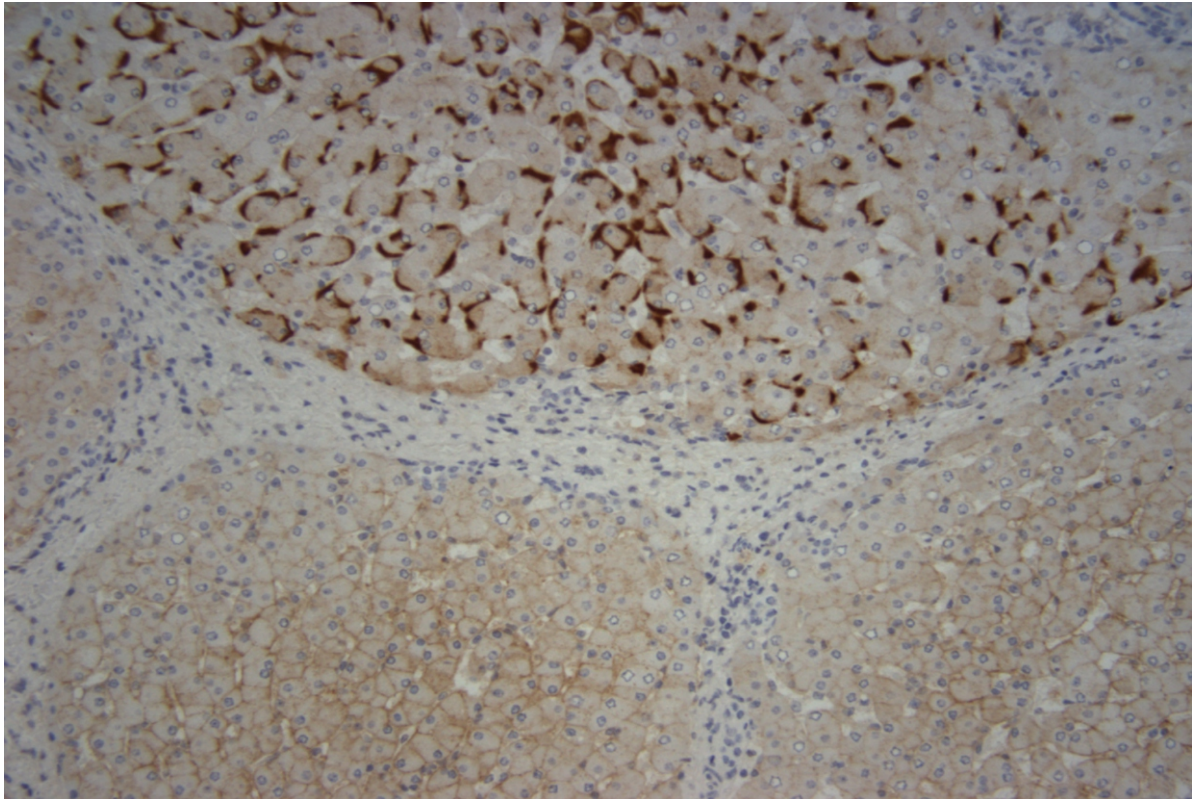


Figure 2: HepBSAg immuno (200x): The background hepatic parenchyma showed cirrhosis, with weak to strong positive immunostaining for Hepatitis B surface antigen

References

1. NIH consensus development statement on management of hepatitis B. NIH Consens State Sci Statements 2008, 25: 1-29.
2. Lok AS, McMahon BJ. Chronic hepatitis B. *Hepatology* 2007, 45: 507-539.
3. Shapiro CN. Epidemiology of hepatitis B. *Pediatr Infect Dis J* 1993, 12: 433-437.
4. Baker SS, Liptak GS, Colletti RB, Croffie JM, Di Lorenzo C, Ector W, et al. Constipation in infants and children: evaluation and treatment. A medical position statement of the North American Society for Pediatric Gastroenterology and Nutrition. *J Pediatr Gastroenterol Nutr* 1999, 29: 612-626.
5. Lai CL, Yuen MF. The natural history and treatment of chronic hepatitis B: a critical evaluation of standard treatment criteria and end points. *Ann Intern Med* 2007, 147: 58-61.
6. Jonas MM, Lok AS, McMahon BJ, Brown RS, Jr., Wong JB, Ahmed AT, et al. Antiviral therapy in management of chronic hepatitis B viral infection in children: A systematic review and meta-analysis. *Hepatology* 2016, 63: 307-318.
7. Kurbegov AC, Sokol RJ. Hepatitis B therapy in children. *Expert Rev Gastroenterol Hepatol* 2009, 3: 39-49.
8. Haber BA, Block JM, Jonas MM, Karpen SJ, London WT, McMahon BJ, et al. Recommendations for screening, monitoring, and referral of pediatric chronic hepatitis B. *Pediatrics* 2009, 124: e1007-1013.
9. Tenney DJ, Rose RE, Baldick CJ, Pokornowski KA, Eggers BJ, Fang J, et al. Long-term monitoring shows hepatitis B virus resistance to entecavir in nucleoside-naïve patients is rare through 5 years of therapy. *Hepatology* 2009, 49: 1503-1514.
10. Watanabe M, Shibuya A, Takada J, Tanaka Y, Okuwaki Y, Minamino T, et al. Entecavir is an optional agent to prevent hepatitis B virus (HBV) reactivation: a review of 16 patients. *Eur J Intern Med* 2010, 21: 333-337.

11. Murray KF, Szenborn L, Wysocki J, Rossi S, Corsa AC, Dinh P, et al. Randomized, placebo-controlled trial of tenofovir disoproxil fumarate in adolescents with chronic hepatitis B. *Hepatology* 2012, 56: 2018-2026.
12. Llovet JM, Ricci S, Mazzaferro V, Hilgard P, Gane E, Blanc JF, et al. Sorafenib in advanced hepatocellular carcinoma. *N Engl J Med* 2008, 359: 378-390.
13. Yu SB, Kim HY, Eo H, Won JK, Jung SE, Park KW, et al. Clinical characteristics and prognosis of pediatric hepatocellular carcinoma. *World J Surg* 2006, 30: 43-50.
14. Lim SG, Mohammed R, Yuen MF, Kao JH. Prevention of hepatocellular carcinoma in hepatitis B virus infection. *J Gastroenterol Hepatol* 2009, 24: 1352-1357.
15. Lai CL, Yuen MF. Prevention of hepatitis B virus-related hepatocellular carcinoma with antiviral therapy. *Hepatology* 2013, 57: 399-408.
16. Papatheodoridis GV, Chan HL, Hansen BE, Janssen HL, Lampertico P. Risk of hepatocellular carcinoma in chronic hepatitis B: assessment and modification with current antiviral therapy. *J Hepatol* 2015, 62: 956-967.
17. Mitchell AE, Colvin HM, Palmer Beasley R. Institute of Medicine recommendations for the prevention and control of hepatitis B and C. *Hepatology* 2010, 51: 729-733.
18. Chen MS, Jr., Dang J. Hepatitis B among Asian Americans: Prevalence, progress, and prospects for control. *World J Gastroenterol* 2015, 21: 11924-11930.
19. Hu KQ. Hepatitis B virus (HBV) infection in Asian and Pacific Islander Americans (APIAs): how can we do better for this special population? *Am J Gastroenterol* 2008, 103: 1824-1833.
20. Hwang JP, Roundtree AK, Engebretson JC, Suarez-Almazor ME. Medical care of hepatitis B among Asian American populations: perspectives from three provider groups. *J Gen Intern Med* 2010, 25: 220-227.
21. Lee H, Yang JH, Cho MO, Fawcett J. Complexity and Uncertainty of Living with an Invisible Virus of Hepatitis B in Korea. *J Cancer Educ* 2010.

Manuscript Information: Received: March 26, 2017; Accepted: July 03, 2017; Published: July 10, 2017

Authors Information: Emily C Hon, MD¹; Kimberly P Newton, MD²; Hyunah Ahn, MD⁴; Denise Malicki, MD, PhD³; Jeannie S Huang, MD, MPH^{2*}

¹Division of Pediatric Gastroenterology, Riley Hospital for Children at IU Health, Indianapolis, IN, USA

²Division of Gastroenterology and Nutrition, Department of Pediatrics, University of California San Diego, and Rady Children's Hospital-San Diego, San Diego, CA, USA

³Division of Pathology, Department of Pediatrics, University of California San Diego, and Rady Children's Hospital-San Diego, San Diego, CA, USA

⁴Division of Hematology-Oncology, Department of Pediatrics, University of California San Diego, and Rady Children's Hospital-San Diego, San Diego, CA, USA

Citation: Hon EC, Newton KP, Ahn H, Malicki D, Huang JS. Hepatocellular carcinoma in an adolescent with Hepatitis B and E-Antigen seroconversion. *Open J Clin Med Case Rep.* 2017; 1283

Copy right statement: Content published in the journal follows Creative Commons Attribution License (<http://creativecommons.org/licenses/by/4.0>). © **Huang JS 2017**

Journal: *Open Journal of Clinical and Medical Case Reports* is an international, open access, peer reviewed Journal focusing exclusively on case reports covering all areas of clinical & medical sciences.

Visit the journal website at www.jclinmedcasereports.com

For reprints and other information, contact editorial office at info@jclinmedcasereports.com