

Spontaneous adrenal hemorrhagic pseudocyst mimicks teratomas: Case report and review of literature

Wei Yongbao*; Li Tao; Le Lin

*Wei Yongbao, MD

Fujian Medical University Teaching Hospital, Fujian Provincial Hospital, No.134 Dong street, Fuzhou 350001, PR China

Phone: +86-15859192139; Email: weiyb2008@163.com

Abstract

Spontaneous Adrenal hemorrhage is a rare lesion of adrenal gland. In this article, a 38-year old man with persistent abdominal pain for two weeks was presented. He was considered as retroperitoneal teratoma based on positive results of abdomen computed tomography scan as a size of 7.1cm×5.0cm mass was found in the right side of retroperitoneal position, characterized by an irregular shape, multi-septated, cross-shaped calcified and unenhanced solid-cystic mass, mimicking teratomas in computed tomography appearance. It presented special features mimicking teratoma on computed tomography and nodular cortical hyperplasia in adrenal gland was observed, which might contribute to the occurrence of hematomas.

Keywords

adrenal hemorrhage; computed tomography; adrenal cortical hyperplasia

Introduction

Adrenal hemorrhage (AH) is a rare lesion of adrenal gland and often observed occasionally in autopsy studies. The causes of AH is considered associated with multiple reasons, such as trauma, stress, hemorrhagic diathesis or coagulopathy, neonatal stress and underlying adrenal tumors [1]. With the increased usage and updating innovation of imaging technology, the diagnosis of AH is increased in recent years [2-4]. Signs and clinical symptoms, together with laboratory findings, are unreliable to identify adrenal hemorrhage, but imaging techniques can help to differentiate hematomas from other adrenal lesions, such as ultrasound, computed tomography (CT) or magnetic resonance imaging (MRI), especially CT scan [1,4-6]. Herein, we presented a unique case of unilateral AH which had developed into pseudocyst mimicking teratomas and was difficult to be distinguished from other adrenal lesions by CT. Furthermore, nodular hyperplasia of adrenal cortex as a very rare cause was observed and might be associated with this AH.

Case Report

A 38-year old man admitted to our emergency department with persistent abdominal pain for two weeks. It was said to occur suddenly without any causes and had no obvious omen. He denied headache, feeling dizzy, inappetence, fever, chilling or emaciation. With unremarkable medical history, he did not

admit having hypertension, diabetes, medications or getting any injuries, as well as tuberculosis or other infectious diseases. Laboratory analysis revealed no special findings. He had a normal level of haemoglobin (160 g/l, normal reference values 130-175 g/L) and normal counts of platelet (342×10^9 /l, normal reference values $125-350 \times 10^9$ /L) and leukemia cells (6.88×10^{12} /L, normal reference values $3.50-9.50 \times 10^9$ /L), together with normal percentage of neutrophils, monocytes and lymphocytes. His liver function, renal function, blood coagulation and routine urinalysis were normal. There was no increase in serum levels of all 12 tumor markers (CA19-9, NSE, CEA, CA242, Ferritin, Beta-HCG, AFP, Free-PSA, Total-PSA, CA125, HGH and CA15-3). He was considered as retroperitoneal teratoma based on positive results of abdomen CT scan. With the aide of CT, a size of 7.1cm×5.0cm mass was found in the right side of retroperitoneal position. Rather, the mass was located in right side of adrenal area, but it seemed not an underlying adrenal neoplasm that originating from adrenal gland, as it seemed more closely related to liver and unable being separated from lower edge of the right lobe of liver. The mass was characterized by an irregular shape, multi-septated, cross-shaped calcified and unenhanced solid-cystic mass, mimicking teratomas in CT appearance (Figure 1A, 1B and 1C). A exploratory laparotomy was performed and the mass was successfully removed. During procedure of intraoperative extrusion and separating, his systolic pressure was once raised up to 180mmHg. He was not found abdominal dropsy, enlargement of lymph nodes or metastases. During operative procedure, the mass was considered originating not from liver but the right adrenal gland. It was completely removed at the expense of resection of a piece of adrenal gland. The pathological examination featured as an outer-layer formation of fibrous capsule, a few lymphocytes infiltration in the wall of capsule, a mass of outmoded blood clots and some striped calcifications in the cyst and partially surrounding by few lesions of nodular cortical hyperplasia (NCH) in adrenal gland (Figure 1D, 1E and 1F). Final diagnosis of a spontaneous adrenal hemorrhagic pseudocyst was made according to pathological results. The patient had a well recovery; adrenal insufficiency and operation related complication was not obtained until his six-month postoperative following-up.

Discussion

In our presenting case, we did not find any confirmed causes resulting in AH as described previously [1], but one interesting phenomenon was observed that NCH of adrenal gland was found surrounding the area of hemorrhage. In fact, we were not confident that if NCH was the real cause of AH in this case, perhaps this finding of AH accompanied with NCH was only a coincidence. However, it was still reasonable to speculate that NCH might contribute to occurrence of this AH. According to previous reports, although the exact mechanism of AH remains largely unknown, several mechanisms for untraumatic adrenal hemorrhage has been proposed [1-3,6-9]. It is believed that any causes which increase in adrenal venous pressure or arterial perfusion pressure may result in hemorrhage into the gland. In our case, firstly, NCH might increase extra-ongoing release of stress hormones, such as hormone cortisol and/or glucocorticoids. This might lead to constriction of the adrenal vein, resulting in increased venous pressure. Secondly, arterial perfusion might be increased to feed into adrenal cortex in which NCH was located. Thirdly, right adrenal gland is more susceptible to damage as the right adrenal vein drains directly into the inferior vena cava [10]. Hence, these elements might be risk factors leading to AH in our case.

The features of CT was quite unique in our case. Michael et al summarized several patterns on CT

for differentiating hematomas from other adrenal lesions, especially differentiating them from adrenal neoplasms [5]. In their studies, they had recognize that adrenal hematomas present variable appearances on CT, including AH appearing as solid round or oval mass, or solid peripheral components with central fluid density, or ill-defined soft tissue because of infiltration of blood, or adreniform enlargement, or amorphous solid mass, and or a rare pattern of active bleeding [5]. According to the previous reports [1,5,6,8,11-13] a unique pattern of appearance on CT mimicking teratoma was firstly observed in our case, presenting as a solid-cystic, multi-septated, cross-shaped calcified and irregular shaped mass. The patterns of AH appearances depend on the age of the bleed and evolve predictably over time due to the different components of acute, subacute, and chronic hemorrhage [1,5].

The unique appearance on CT in our case might due to a unique age of AH.

Surgical exploration and nonoperative management are two different methods towards AH. Surgical exploration was once a priority management [14], however, nonoperative one presents an overall trend in successfully treating AH, including supportive care, measurement of serial hematocrits, blood transfusions and angioembolization [1,15]. However, in our case, not AH but retroperitoneal teratoma was firstly considered, laparotomy was performed to remove the mass. In our opinion, when an accurate diagnosis of AH is difficult to make and obvious local symptoms or signs persist, together with calcification, organization and resisting dissolution in the mass, surgical remove may still be a reconsidered alternative choice to treat AH.

Figure

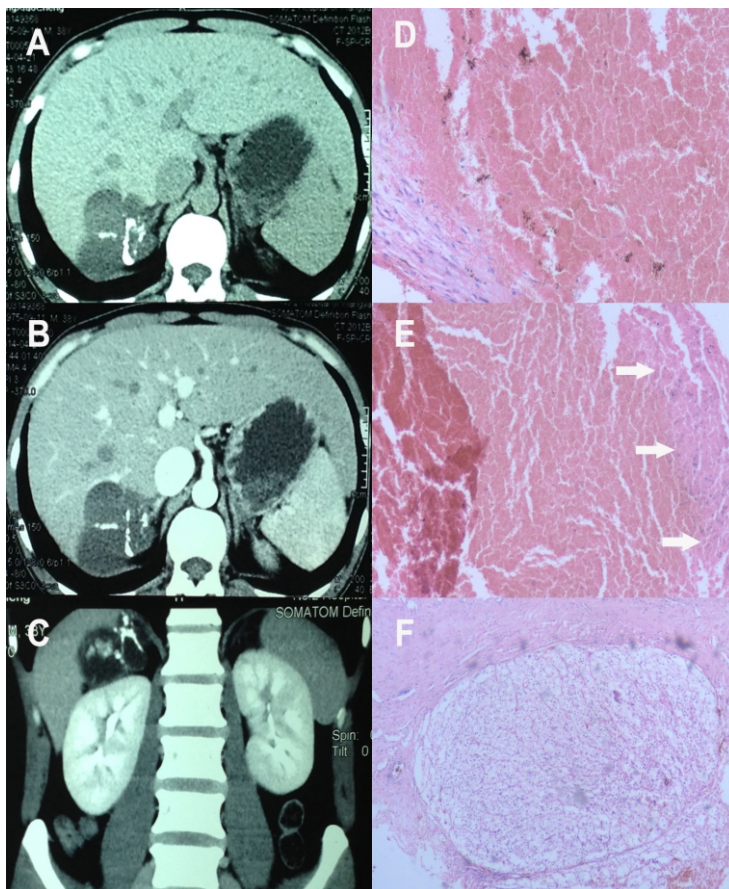


Figure 1: Features on CT and pathological results of adrenal hemorrhagic pseudocyst.

(1A) Axial unenhanced, (1B) axial enhanced and (1C) coronal enhanced CT scan present unenhanced solid-cystic mass, mimicking teratomas, which was close to the right lobe of liver, with an irregular shape, multi-septated and cross-shaped calcified appearance. The value of Hounsfield unit (HU) on CT for calcification was 1000 HU, while the rest area was about -10 to 30HU.

(1D and 1E) massive blood clots were obtained in the pseudocyst (H&E staining; magnification, x100). (1D) the cyst wall of pseudocyst formed by connective tissue with few lymphocytes infiltrated. (1E) purplish blue calcifications was noted among blood clots (white arrows). (1F) nodular cortical hyperplasia was found in the adrenal gland linking to the pseudocyst (H&E staining; magnification, x100).

Conclusion

In conclusion, a unique case of spontaneous adrenal hemorrhage was presented. It presented special features mimicking teratoma on CT, as well as nodular cortical hyperplasia in adrenal gland was observed, which might be a first-observed cause that contributed to the occurrence of hematomas.

References

1. Simon DR, Palese MA. Clinical update on the management of adrenal hemorrhage. *Curr Urol Rep* 2009;10:78-83.
2. Francque SM, Schwagten VM, Ysebaert DK, Van Marck EA, Beaucourt LA. Bilateral adrenal haemorrhage and acute adrenal insufficiency in a blunt abdominal trauma: a case-report and literature review. *Eur J Emerg Med* 2004;11:164-7.
3. You JS, Chung SP, Park YS, Chung HS, Lee HS, Yu JS. Isolated adrenal hemorrhage after minor blunt trauma. *Am J Emerg Med* 2007;25:984-5.
4. Sivit CJ, Ingram JD, Taylor GA, Bulas DI, Kushner DC, Eichelberger MR. Posttraumatic adrenal hemorrhage in children: CT findings in 34 patients. *Am J Roentgenol* 1992;158:1299-302.
5. Sacerdote MG, Johnson PT, Fishman EK. CT of the adrenal gland: the many faces of adrenal hemorrhage. *Emerg Radiol* 2012;19:53-60.
6. Hoeffel C, Legmann P, Luton JP, Chapuis Y, Fayet-Bonnin P. Spontaneous unilateral adrenal hemorrhage: computerized tomography and magnetic resonance imaging findings in 8 cases. *J Urol* 1995;154:1647-51.
7. Rosenberger LH, Smith PW, Sawyer RG, Hanks JB, Adams RB, Hedrick TL. Bilateral adrenal hemorrhage: the unrecognized cause of hemodynamic collapse associated with heparin-induced thrombocytopenia. *Crit Care Med* 2011;39:833-8.
8. Ferreira JG, Borr ML, Menasce S, Ajzen S, Kater CE, Faical S. Acute adrenal haemorrhage: diagnosis, treatment and follow-up. *Int Urol Nephrol* 1996;28:735-41.
9. Piccioli A, Chini G, Mannelli M, Serio M. Bilateral massive adrenal hemorrhage due to sepsis: report of two cases. *J Endocrinol Invest* 1994;17:821-4.
10. SEVITT S. Post-traumatic adrenal apoplexy. *J Clin Pathol* 1955;8:185-94.
11. Taguchi T, Inoue K, Terada Y. Concentric-ring sign in adrenal hemorrhage. *Endocrine* 2014;47:965-6.
12. Bockorny B, Posteraro A, Bilgrami S. Bilateral spontaneous adrenal hemorrhage during pregnancy. *Obstet Gynecol* 2012;120:377-81.
13. Kably MI, Zamiati W, Benkirane H, Kadiri R. [Massive bilateral adrenal hemorrhage: role of imaging]. *J Radiol* 2004;85:652-4.
14. Gomez RG, McAninch JW, Carroll PR. Adrenal gland trauma: diagnosis and management. *J Trauma* 1993;35:870-4.
15. Liao CH, Ouyang CH, Fu CY, Wang SY, Lin KJ, Kuo IM, Hsu CP, Yang SJ, Yuan KC, Hsu YP. The current status and management of blunt adrenal gland trauma. *Surgery* 2015;157:338-43.

Manuscript Information: Received: March 04, 2017; Accepted: May 17, 2017; Published: May 19, 2017

Authors Information: Wei Yongbao*; Li Tao; Le Lin

Department of Urology, Fujian Medical University Teaching Hospital, Fujian Provincial Hospital, Fuzhou 350001, China

Citation: Yongbao W, Tao L, Lin L. Spontaneous adrenal hemorrhagic pseudocyst mimicks teratomas: Case report and review of literature. Open J Clin Med Case Rep. 2017; 1261

Copy right statement: Content published in the journal follows Creative Commons Attribution License (<http://creativecommons.org/licenses/by/4.0>). © **Yongbao W 2017**

Journal: Open Journal of Clinical and Medical Case Reports is an international, open access, peer reviewed Journal focusing exclusively on case reports covering all areas of clinical & medical sciences.

Visit the journal website at www.jclinmedcasereports.com

For reprints and other information, contact editorial office at info@jclinmedcasereports.com