

A rare case of clostridium difficile (Pseudomembranous) colitis of right colon presenting with intestinal obstruction

Hari Govind S; Hirdaya H Nag*; Ashish Sachan; Siddharth Shrivastava

*Hirdaya H Nag

Department of Gastrointestinal Surgery , G B Pant Institute of Post graduate Medical Education and Research, Jawaharlal Nehru Marg, New Delhi-110002

Phone: +91 97 1859 9260; Email: harisurge@gmail.com

Abstract

90 % of Clostridium difficile colitis (CDC) is preceded by antibiotic therapy. CDC commonly presents with abdominal pain and loose stools. But 10 % of them present with features of intestinal obstruction. There are four cases reports published in literature on this rare mode of presentation, all of the four being left sided colonic obstruction.

This report was based on a post operative case of choledochal cyst who had developed intestinal obstruction on eighth post operative day (POD) associated with fever , tachycardia and leucocytosis which was diagnosed as CDC with the aid of computerised tomography of abdomen , colonoscopy and biopsy and stool cytotoxin assay. The patient was managed conservatively with oral vancomycin and metronidazole and intraluminal vancomycin therapy. Her symptoms gradually subsided and was discharged on twenty sixth POD.

CDC should be managed with antibiotics and conservative management and threshold for surgery should be kept very high unless complications of colitis itself warrant urgent surgical intervention.

Keywords

clostridium difficile colitis; pseudomembranous colitis; intestinal obstruction; right colon

Abbreviations

CDC: Clostridium difficile colitis; i.v: Intravenous; POD: post operative day; TLC: Total Leucocyte count

Introduction

Clostridium difficile colitis (CDC) or pseudomembranous colitis is an inflammatory pathology of the bowel caused by toxins produced by unopposed proliferation of the bacterium *Clostridium difficile*. Antibiotic use continues to precede almost all cases of CDC. Cephalosporins, clindamycin, fluoroquinolones and ampicillin-amoxicillin were most commonly associated with CDC. Of patients with CDC, 90% have received antibiotic therapy. Antibiotic therapy leads to change in colonic microflora which facilitates growth of nosocomial organisms which produce toxins. Toxin B enters the portal circulations and in liver it elaborates many cytokines which causes systemic inflammatory response.

Watery diarrhoea is the hallmark symptom. Severe colitis presents with abdominal cramps,

anorexia, dehydration, tachycardia and leucocytosis. Pseudomembranous colitis is the more dramatic form of the disease and develops in 40% of patients who are significantly symptomatic [1-3]. CDC rarely presents with features of intestinal obstruction. Till date there are only four case reports of CDC complicated by intestinal obstruction – one in child and three in adults. All the four cases had left sided colitis with subsequent left colon obstruction. This is the first case of CDC presenting with right sided colonic obstruction.

Case Report

A 45 year old immunocompetent female patient underwent surgery (Choledochal Cyst Excision with Roux en Y Hepaticojejunostomy) for Type I choledochal cyst with cystolithiasis (with Endoscopic biliary stenting done for cholangitis 3 months before) on 15/6/16. Post operatively she was given Piperacillin with Tazobactam (4.5g i.v eighth hourly) and Amikacin (750 mg once daily) for 3 days according to institutional protocol for patients with biliary stent in situ . She was started on oral feeds on fifth post operative day (POD) which she tolerated initially. She had abdominal distention from eighth POD with features suggestive of intestinal obstruction. Even though she had constipation she had occasional very minimal amount of loose stools mixed with blood and mucus. She was evaluated with X-ray abdomen which revealed features suggestive of proximal colonic obstruction (Figure 1). Clinically she had signs of mechanical bowel obstruction. She was managed with nasogastric continuous drainage (800 ml on first day) and intravenous fluids. She had associated tachycardia (100 to 120 per minute) with intermittent spikes of hyperthermia (maximum 103° F). Her total leucocyte count (TLC) was 38,000 / cu mm on tenth post operative day. She was evaluated with abdominal sonography which was unremarkable. So computerised tomography abdomen with oral and intravenous contrast was done which revealed diffuse circumferentially thickened ascending colon and cecum with non passage of contrast distally (Figure 2). They gave a provisional diagnosis of pseudomembranous colitis or ischemic colitis. Previous antibiotics was stopped and oral vancomycin and metronidazole was started along with probiotics.

Gastromedicine consultation was sought and colonoscopy was advised. Colonoscopy was done on twelfth POD which revealed thickened erythematous, friable mucosa in the cecum and ascending colon with white membranes over it (Figure 3). Tissue for histopathology was taken, the report of which showed presence of granulation tissue and inflammatory exudates which was non specific. Stool sample was sent for difficile toxin assay which revealed the presence of toxin (normal stool specimen will be devoid of Clostridium difficile toxin). Stool cytotoxin assay has a sensitivity of 70 to 100 % and a specificity of 90 to 100 % in diagnosing CDC [4]. So a definitive diagnosis of CDC was made based on toxin assay, CECT scan and colonoscopic findings . Gradually fever, tachycardia and TLC decreased. But inspite of all conservative measures, her symptoms of intestinal obstruction did not subside. Repeat CECT abdomen was done on eighteenth POD which showed decrease in thickening of colonic wall with mild passage of contrast distally. So, in consensus with gastrophysician, colonoscopic intraluminal vancomycin was instilled. Two days later, she passed stools which was of normal consistency and colour and gradually abdominal symptoms subsided. Nasogastric tube was removed and was started on oral liquids. Gradually oral feeds were increased which she tolerated well. She was discharged on twenty sixth POD (Figure 4). On three month follow up she was asymptomatic.

Discussion

CDC usually presents with loose stools (85 to 90 %) and fever and very rarely presents with features of intestinal obstruction. Four case reports [5-8] have already been published on this rare presentation of mechanical intestinal obstruction secondary to pseudomembranous colitis. But what makes this case distinct from others is the site of pathology. CDC usually affects left colon and presence of pseudomembrane is limited to proximal colon in only 10 % of cases. In this case, cecum and ascending colon was affected. In view of the rarity of the entity, it was difficult to keep CDC with intestinal obstruction as our working diagnosis before contemplating on any diagnostic imaging and endoscopy. In all other published reports, CDC was involving left sided colon. Colonoscopy, which is an important armamentarium in diagnosing CDC would be easier in left sided colonic disease rather than the right sided pathology, as bowel preparation of right colon in a patient with obstruction is difficult. Still with multiple bowel washes and enema we could prepare the colon for colonoscopy in a reasonable manner. Like in one previous report, we attempted intraluminal vancomycin administration, two days after which abdominal symptoms subsided [5]. Resolution of symptoms may be attributed to this mode of therapy, the significance of which needs to be investigated further.

In light of this case report it may be suggested that cases of CDC with intestinal obstruction, however severe it is (except toxic megacolon, perforation and stricture), do not warrant surgical intervention and can be managed by wait and watch policy with oral or intraluminal vancomycin or metronidazole therapy. Acute fulminant colitis, toxic megacolon and its further sequelae occurs in 2 to 5% of patients with CDC which may require emergency surgical intervention. Three of the four patients in the published case reports were successfully managed with conservative medical measures. In a case report by Zhu et al, where they retrospectively diagnosed CDC after colectomy in a patient with mid sigmoid stricture, sigmoidoscopy did not reveal any mucosal abnormalities [8]. This may be attributed to the fact that the patient did not have active colitis during the episode of obstruction (which was due to inflammatory stricture). Post operative adhesive intestinal obstruction (which was our initial working diagnosis) may be managed conservatively for a few days. But if the patient does not show signs of improvement in 2 to 3 days or gets deteriorated (according to our institutional protocol), surgery will be advisable on a semi emergent basis. But in CDC which is amenable to treatment with antibiotics and conservative management, threshold for surgery should be kept very high unless complications of colitis itself warrant urgent surgical intervention.

Figures

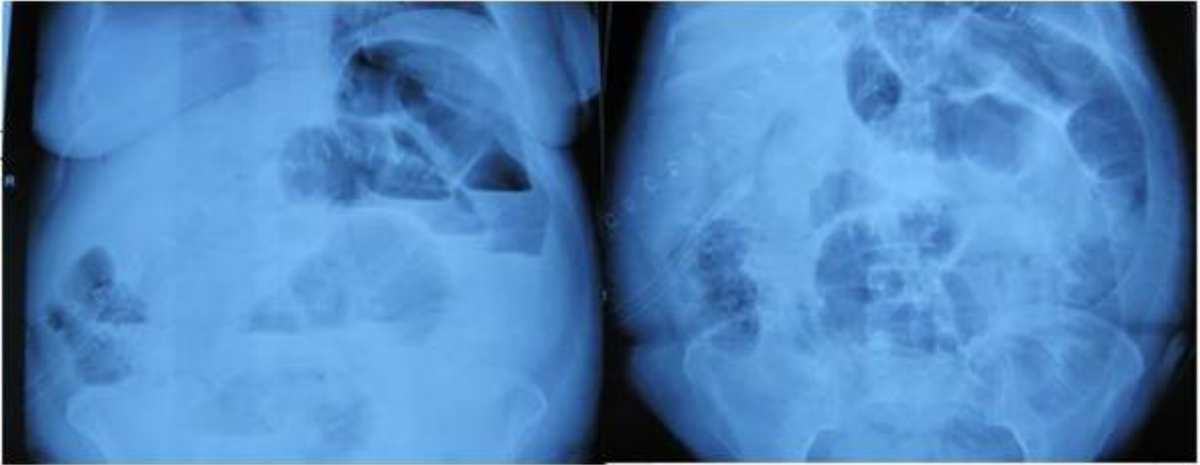


Figure 1: Radiograph of abdomen showing dilated small bowel loops and air fluid levels (POD 8)

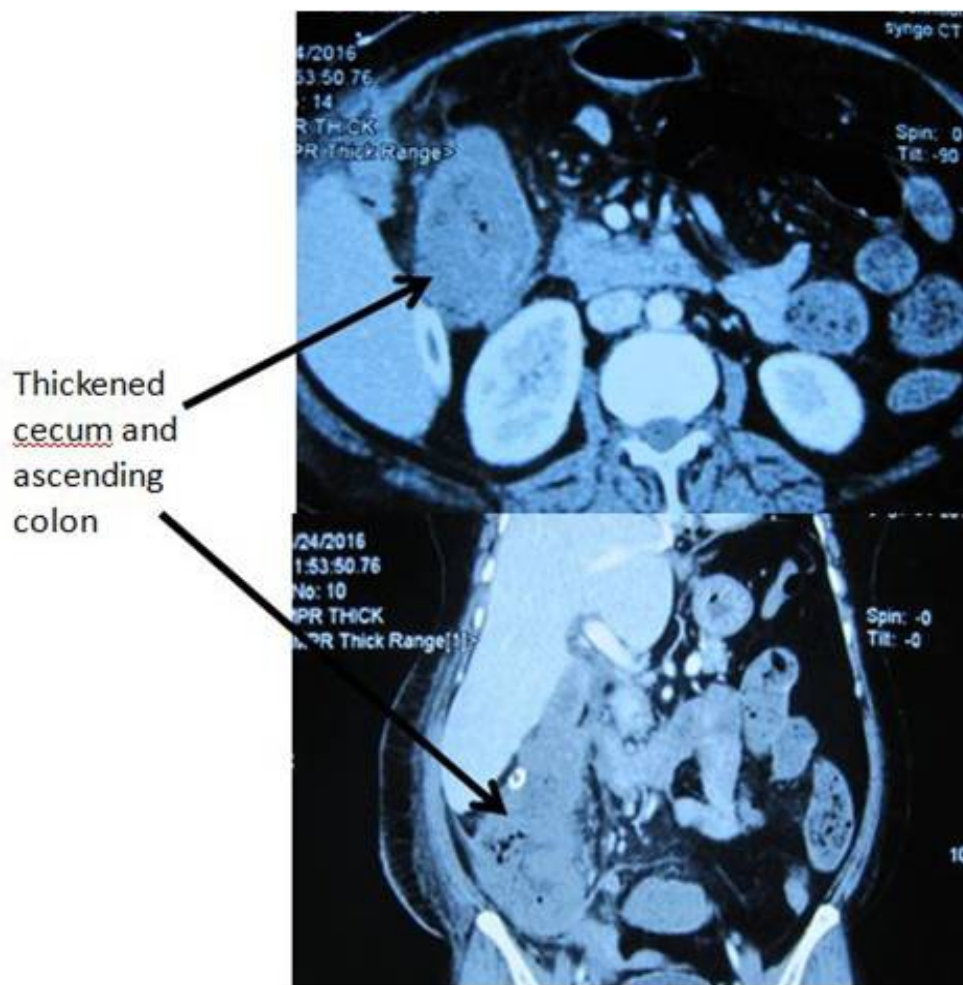

Figure 2: CECT abdomen with oral contrast showing circumferentially thickened Ascending colon with dilated small bowel loops

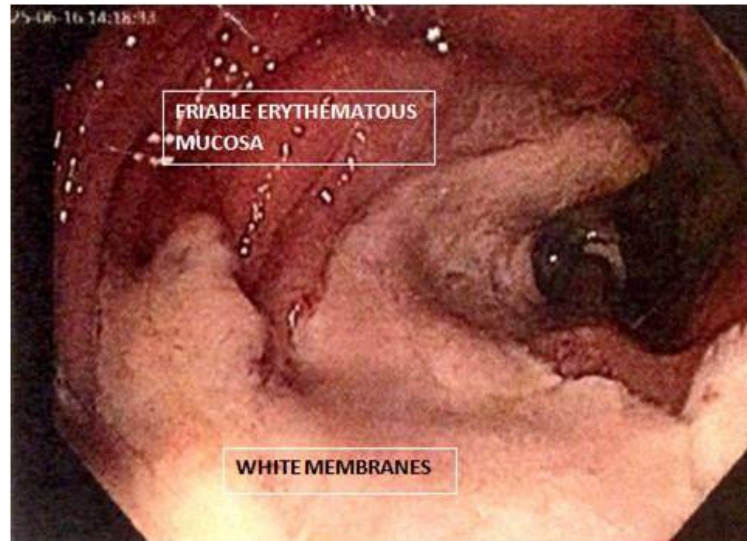


Figure 3: Colonoscopic finding of pseudomembranous colitis

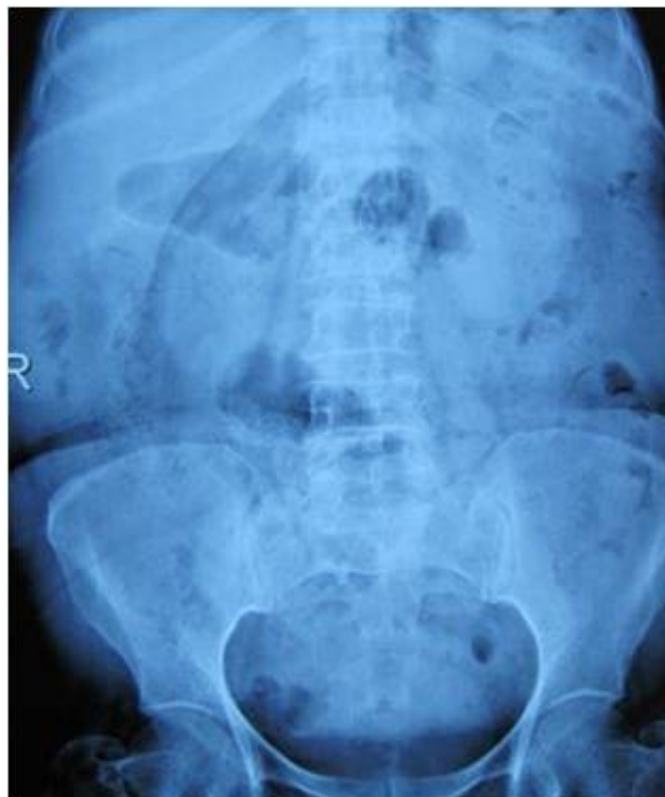

Figure 4: Radiograph of abdomen showing resolution of Intestinal obstruction

References

1. Seder CW, Villalba MR, Jr, Robbins J, et al: Early colectomy may be associated with improved survival in fulminant *Clostridium difficile* colitis: An 8-year experience. *American Journal of Surgery* 197:302–307, 2009.
2. Sailhamer EA, Carson K, Chang Y, et al: Fulminant *Clostridium difficile* colitis: Patterns of care and predictors of mortality. *Archives of Surgery* 144:433–439; discussion 439–440, 2009.
3. Pepin J, Vo TT, Boutros M, et al: Risk factors for mortality following emergency colectomy for fulminant *Clostridium difficile* infection. *Diseases of Colon and Rectum* 52:400–405, 2009.
4. Turgeon DK, Novicki TJ, Quick J et al: Six rapid tests for direct detection of *Clostridium difficile* and its toxins in fecal samples compared with the fibroblast cytotoxicity assay. *Journal of Clinical Microbiology* 2003;41:667-70.

5. Kenichi Nomura, Kohei Fukumoto, Daisuke Shimizu et al : Pseudomembranous colitis presenting as acute colonic obstruction without diarrhea in a patient with gastric Burkitt lymphoma, World Journal of Gastroenterology 2005;11(17):2681-2683.
6. Sheikh R A , Yasmeen S, Pauly MP , Trudeau WL : Pseudomembranous colitis without diarrhea presenting clinically as acute intestinal pseudo-obstruction. Journal of Gastroenterology 2001; 36: 629-632.
7. Miholic J, Weninger M, Helmer F, Khoss A, Lessky E, Pollak A : Antibiotic-associated pseudomembranous colitis as cause of intestinal obstruction in a five-day-old newborn, Padiatr Padol. 1986;21(2):183-7.
8. Katherine J. Zhu, Robert Winn . Pseudomembranous colitis presenting as a mechanical large bowel obstruction, ANZ Journal of surgery ,2016.

Manuscript Information: Received: January 25, 2017; Accepted: April 26, 2017; Published: April 28, 2017

Authors Information: Hari Govind S¹; Hirdaya H Nag^{1*}; Ashish Sachan¹; Siddharth Shrivastava²

¹Department of Gastrointestinal Surgery , G B Pant Institute of Post graduate Medical Education and Research, New Delhi, India.

²Department of Gastromedicine, G B Pant Institute of Post graduate Medical Education and Research, New Delhi, India.

Citation: Govind SH, Nag HH, Sachan A, Shrivastava S. A rare case of clostridium difficile (Pseudomembranous) colitis of right colon presenting with intestinal obstruction. Open J Clin Med Case Rep. 2017; 1252

Copy right statement: Content published in the journal follows Creative Commons Attribution License (<http://creativecommons.org/licenses/by/4.0>). © Nag HH 2017

Journal: Open Journal of Clinical and Medical Case Reports is an international, open access, peer reviewed Journal focusing exclusively on case reports covering all areas of clinical & medical sciences.

Visit the journal website at www.jclinmedcasereports.com

For reprints and other information, contact editorial office at info@jclinmedcasereports.com