

Ocular associations of myelinated retinal nerve fibers: A study based on a case report

Sonay Beyatli, BS; Yasemin Polat, BS; Ali Riza Cenk Celebi, MD, FEBO*

*Ali Riza Cenk Celebi, MD, FEBO

Acibadem University School of Medicine Department of Ophthalmology Turgut Ozal Boulevard, No: 16, Kucukcekmece, Istanbul 34303, Turkey

Phone: 90 212 404 40 84 , Fax: 90 212 404 48 39; Email: arcenkcelebi@gmail.com

Abstract

Purpose: The purpose of this case report is to present a patient with unilateral isolated myelinated retinal nerve fibers (MRNFs) with its differential diagnosis.

Case presentation: A 34 year-old man admitted for a routine annual checkup examination. His slit lamp biomicroscopic examination of both eyes and dilated fundus examination of the right eye were all within normal limits. Dilated fundus examination of the left eye revealed the presence of white-grey patch like lesion on the upper temporal quadrant of the retina unrelated to the optic nerve head. The appearance of the lesion was consistent with the MRNF. Visual field exam revealed absolute scotomas corresponding to the MRNF site. Systemic examination of the patient was unremarkable.

Conclusion: In cases of MRNFs it is essential to perform clinical investigations to determine the precise location of and potential etiological factors and ocular associations for MRNFs.

Keywords

MRNFs; biomicroscopy; absolute scotomas

Introduction

Myelin accelerates the transmission of the electrical signals along the myelin nerve fibers [1]. The myelination of the retinal ganglion cell axons starts from the geniculate body in the intrauterine life and it ends at the level of lamina cribrosa in the postnatal period. This suggests that lamina cribrosa is a barrier to myelination [2-4]. Myelinated retinal nerve fibers (MRNFs) originate as a result of abnormal migration of oligodendrocyte-like glial cells into the retina prior to the development of the barrier function of the lamina cribrosa [5]. MRNFs could be associated with a developmental anomaly or due to a consequence of an acquired damage to the integrity of the lamina cribrosa [5]. Most of the MRNFs are congenital or asymptomatic but it is also possible for a patient to acquire this pathology during his/her lifetime [6]. Congenital MRNFs are present in 0.3-0.6% of the population [7]. Retinal myelination can also occur in surgical procedures, such as optic nerve decongestion [8]. In some cases, partial or total regression of myelinated retinal nerve fiber has been observed after multiple sclerosis, glaucoma, Behçet's disease and intraocular surgery and retinal arterial occlusion [9]. Patients with myelinated nerve fibers are usually asymptomatic unless there is foveal involvement causing visual.

In this article we aimed to review the differential diagnosis and the ocular associations of the MRNFs based on a case with atypical MRNF distribution in a healthy eye.

Case Presentation

A 34 year-old man was admitted to our clinic for a routine checkup examination. Not any systemic abnormality was found with his physical examination. He denied using any kind of medication. Comprehensive ophthalmological examination including visual acuity test, slit lamp biomicroscopy and dilated funduscopy were performed. The best corrected visual acuity was measured as 1.0 at his both eyes. Slit lamp biomicroscopy findings on both eyes were unremarkable. Dilated fundus examination of the left eye revealed the presence of myelinated retinal nerve fibers on the upper temporal quadrant of the retina (Figure 1). On visual field exam, absolute scotomas were noticed at 51st, 52nd and 53rd points of regions at 24-2 Humphrey Visual Field print out (Figure 2).

Discussion

The process of optic nerve myelination starts at the 32nd week of the gestational period, originating from the lateral geniculate nucleus [10]. The exact mechanism of retinal fiber myelination is still unknown. Myelinated retinal nerve fibers are defined as 'isolated white-grey lesions' obscuring the retinal layers [5]. There are several hypothesis which have been discussed over the decades. The first hypothesis states that the lamina cribrosa prevents the passage of oligodendrocytes to the retina whereas some scientists claim that myelination is mostly related to the blood brain barrier control system or to the proteoglycan controlled continuity of axonal parts [11]. The histopathological assessment of MRNFs showed no microscopic evidence of inflammation with few cell nuclei [12]. Increased thickness of the nerve fiber layer compresses the underlying retinal layers, causing alterations in the conformation of the inner and outer plexiform layers associated with the degenerative signs of myelinolysis [12]. This has resulted as an indistinct border between the inner nuclear layer and outer nuclear layer, leading to the formation of condensed myelin with a larger axonal diameter [12].

Association of widespread myelinated retinal nerve fibers with abnormalities such as myopia, amblyopia, strabismus and afferent pupillary defects was questioned in earlier studies [13]. A case report of a 4 year- old girl was discussed to understand the reason of amblyopia in patients with MRNFs. It was stated that MRNFs induce the elevation of optic disc, leading to disorganized neural elements [13]. In a recent study including 6 children, SD-OCT's were taken from the fovea and the peripapillary area. Fundus was compared with the location of the regional excavation in the sclera according to the distribution of the MRNF in the photograph. Focal scleral excavation was found to have a significant correlation with the 12-hour distribution of the myelinated area in SD-OCT circular scan. There was a significant correlation between the brunch membrane tilt and the distribution of MRNF in the vertical sections of SD-OCT. We conclude that the localized scleral excavation is strongly associated with the distribution of MRNF resulted in the development of axial myopia [14]. However, our patient didn't show any reflective abnormality of myopia or amblyopia.

General and ocular abnormalities reported with myelinated retinal nerve fibers are; coloboma, polycoria, keratoconus, oxycephalia, and other forms of dyscrania [9]. Gorlin (multiple basal cell nevus) syndrome, Albright hereditary osteodystrophy, GAPO syndrome (an autosomal recessive syndrome

associated with growth retardation, alopecia, pseudoanodontia and optic atrophy) are examples of the reported familial cases of isolated MRNFs [9]. A recent population based study showed a positive association between the history of stroke and MRNFs [16,17]. Due to our patient's young age and devoid of systemic associations (hypertension, diabetes), we did not find a link between stroke and MRNFs in our patient. Retinal breaks, vitreous hemorrhage, vitreo-macular traction may also be seen in the myelinated regions. We presented a list of ocular associations in a patient who has MRNF (Table). MRNFs may be confused with a cotton-wool spot, retinal artery branch occlusion, peripapillary epiretinal membrane or retinal pigment epithelium detachment, retinal infiltrate and even retinoblastoma with leukocoria [12,18].

Conclusion

In conclusion, we have presented a patient with unilateral isolated MRNFs with discussing the differential diagnosis and ocular associations. In cases of MRNFs, it is essential to perform clinical examinations to investigate other ocular associations and potential etiological factors concurring with MRNFs and should be assessed with detailed tests if necessary.

Figures

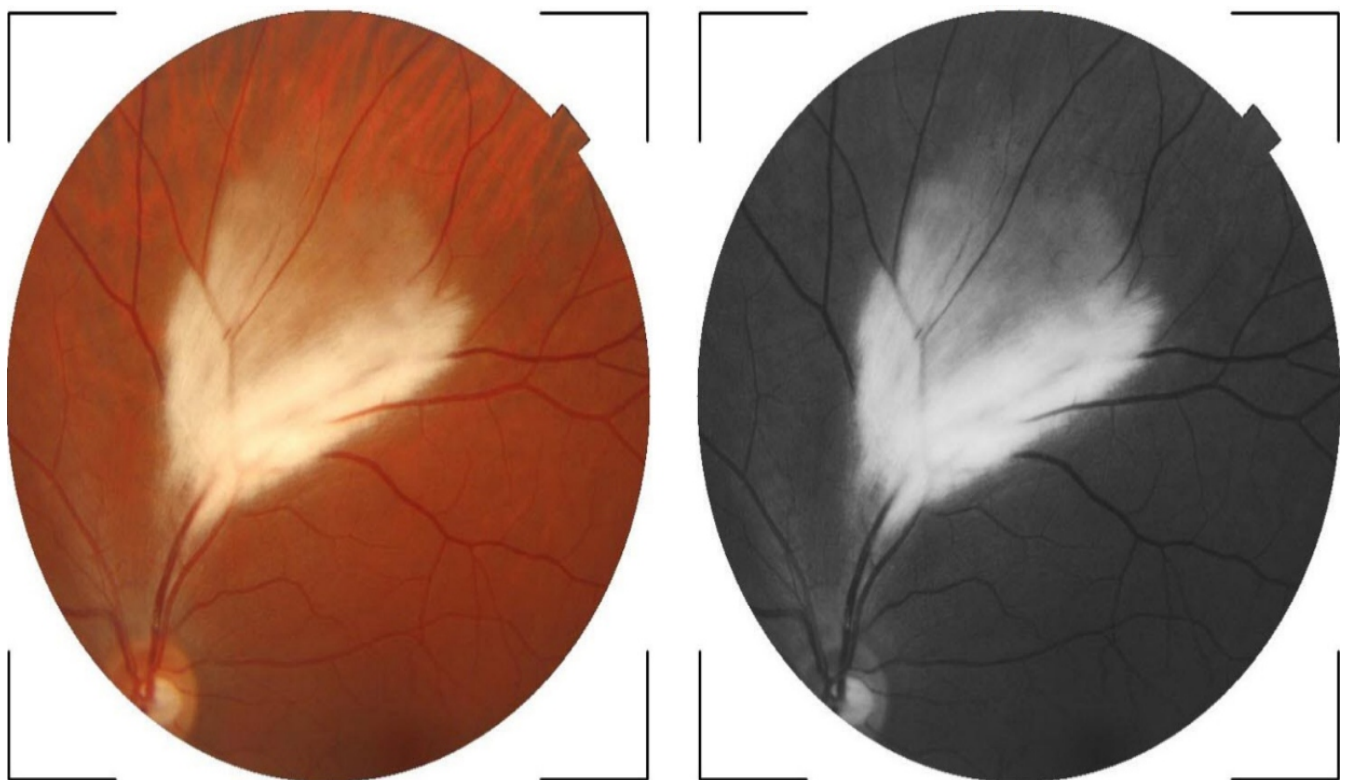

Figure 1: Fundus photography and red free picture of the left eye

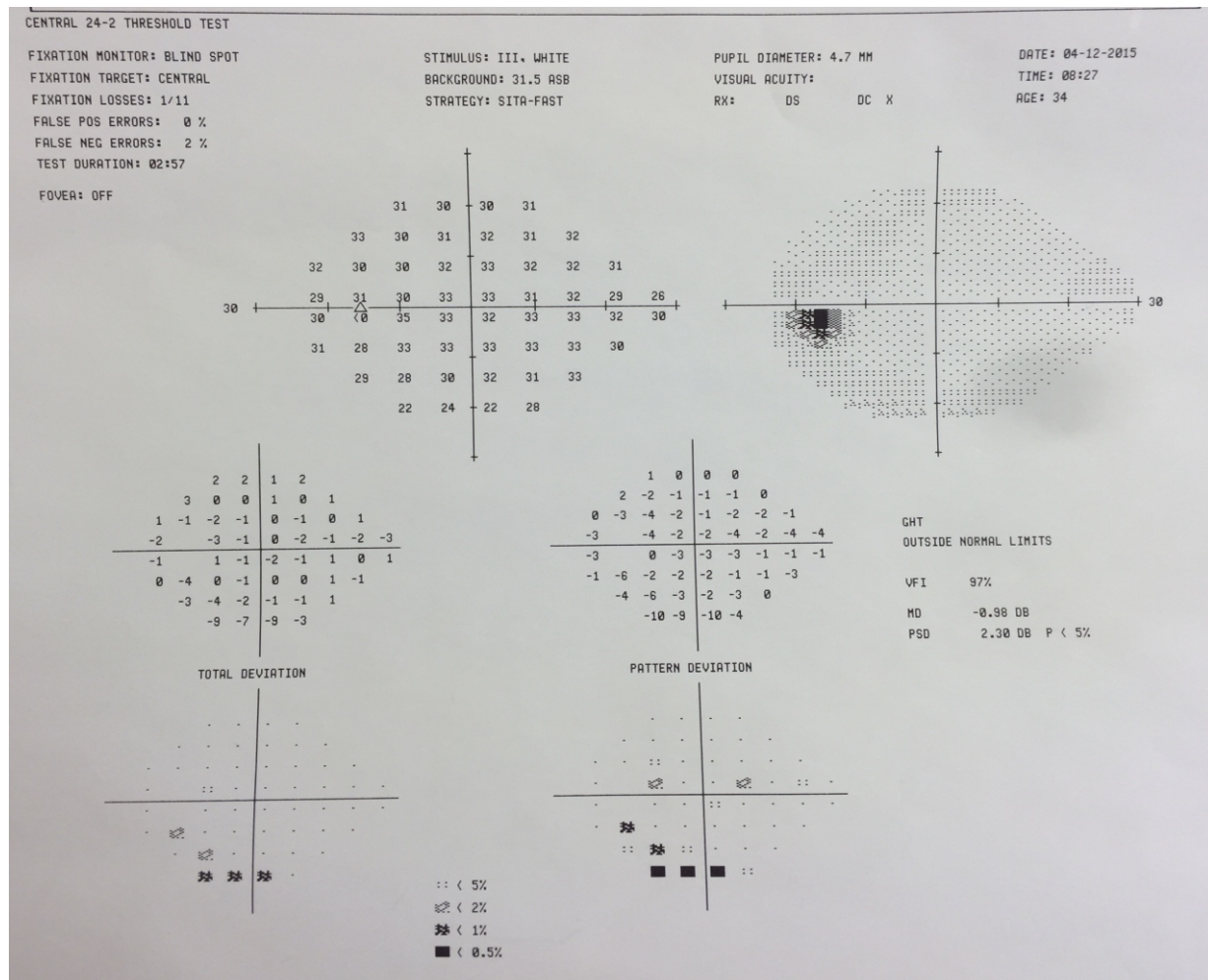


Figure 2: Corresponding visual field test of the left eye

Table

Table 1: Ocular Associations of MRNF

<u>Anterior segment:</u>	<u>Optic nerve associated:</u>
Prominent Schwalbe's line	Afferent pupillary deficit
Polycoria	Visual field deficits
Keratoconus	Optic nerve hypoplasia and dysplasia
Congenital cataracts	Optic nerve head drusen
<u>Refractive and Sensorimotor:</u>	<u>Uveal and Retinal:</u>
Anisometropic Myopia	Uveal Coloboma
Amblyopia	Retinal breaks
Monocular nystagmus	Vitreomacular traction syndrome
Strabismus	Epiretinal membrane
	Chroiditis
	Uveitis
	Retinal detachment
	Macular thickening
	Retinal vascular complications
	Telangiectasias
	Recurrent vitreous hemorrhage

References

1. Schmidt D, Meyer JH, Brandi-Dohrn J. Wide-spread myelinated nerve fibers of the optic disc: do they influence the development of myopia? *Int Ophthalmol.* 1996-1997;20(5):263-8.
2. Straatsma BR, Foos RY, Heckenlively JR, Taylor GN. Myelinated retinal nerve fibers. *Am J Ophthalmol.* 1981 Jan;91(1):25-38.
3. Nourinia R, Behdad B, Montahaei T. Optical coherence tomography findings in a patient with myelinated retinal nerve fiber layer. *J Ophthalmic Vis Res.* 2013 Jul;8(3):280-1.
4. Moradian S, Karim S. Unilateral myelinated retinal nerve fiber layer associated with axial myopia, amblyopia and strabismus. *J Ophthalmic Vis Res.* 2009 Oct;4(4):264-5.
5. Tarabishy AB, Alexandrou TJ, Traboulsi EI. Syndrome of myelinated retinal nerve fibers, myopia, and amblyopia: A Review. *Surv Ophthalmol.* 2007; 52: 588-596.
6. Grzybowski A, Winiarczyk I. Myelinated retinal nerve fibers (MRNF) - Dilemmas related to their influence on visual function. *Saudi J Ophthalmol;* 29: 85-88.
7. Cinar E, Zengin MO, Kucukerdonmez C. Prevalence and clinical characteristics of myelinated retinal nerve fibres: a cross-sectional study of Turkish individuals between 8 and 75 years. *Acta Ophthalmol.* 2015; 93: 599-600.
8. Aaby AA, Kushner BJ. Acquired and progressive myelinated nerve fibers. *Arch Ophthalmol.* 1985 Apr;103(4):542-4.
9. Elbaz H, Peto T, Butsch C, Orouji E, Laubert-Reh D, Ponto KA, Mirshahi A. Prevalence And Associations Of Myelinated Retinal Nerve Fibers. *Retina* 2016 Jun 2 [Epub ahead of print].
10. Yalcın E, Balcı O, Akingol Z. Association of Extensive Myelinated Nerve Fibers and High Degree Myopia: Case Report. *Indian J Ophthalmol.* 2013; 61: 606-607.
11. Shenoy R, Bialasiewicz AA, Al Barwani B. Bilateral hypermetropia, myelinated retinal nerve fibers, and amblyopia. *Middle East Afr J Ophthalmol* 2011; 18: 65-66.
12. Straatsma BR, Foos RY, Heckenlively JR, Taylor GN. Myelinated retinal nerve fibers. *Am J Ophthalmol* 1981; 91: 25-38.
13. Moradian S, Karimi S. Unilateral myelinated retinal nerve fiber layer associated with axial myopia, amblyopia and strabismus. *J Ophthalmic Vis Res* 2009; 4: 264-265.
14. Oh BL, Hwang JM, Woo SJ. Myelinated nerve fiber- associated local scleral excavation and induced axial myopia. *Retina.* 2014 Oct;34(10):2028-36.
15. Schmidt D, Meyer JH, Brandi-Dohrn J. Wide-spread myelinated nerve fibers of the optic disc: do they influence the development of myopia? *Int Ophthalmol.* 1996-1997;20(5):263-8.
16. Straatsma BR, Heckenlively JR, Foos RY, & Shahinian JK. Myelinated retinal nerve fibers associated with ipsilateral myopia, amblyopia, and strabismus. *Am J Ophthalmol* 1979; 88: 506-510.
17. Cinar E, Zengin MO, Kucukerdonmez C. Prevalence and clinical characteristics of myelinated retinal nerve fibres: a cross-sectional study of Turkish individuals between 8 and 75 years. *Acta Ophthalmol.* 2015 Nov;93(7):e599-600.
18. Shelton JB, Digre KB, Gilman J, Warner JE, Katz BJ. Characteristics of myelinated retinal nerve fiber layer in ophthalmic imaging: findings on autofluorescence, fluorescein angiographic, infrared, optical coherence tomographic, and red-free images. *JAMA Ophthalmol.* 2013 Jan;131(1):107-9.

Manuscript Information: Received: January 30, 2016; Accepted: March 10, 2017; Published: March 15, 2017

Authors Information: Sonay Beyatli, BS¹; Yasemin Polat, BS²; Ali Riza Cenk Celebi, MD, FEBO^{1*}

¹Department of Ophthalmology, Acibadem University School of Medicine, Istanbul, TURKEY

²Leiden University Medical Center, Leiden, NETHERLANDS

Citation: Beyatli S, Polat Y, Celebi AR. Ocular associations of myelinated retinal nerve fibers: A study based on a case report. Open J Clin Med Case Rep. 2017; 1233

Copy right statement: Content published in the journal follows Creative Commons Attribution License (<http://creativecommons.org/licenses/by/4.0>). © Celebi AR 2017

Journal: Open Journal of Clinical and Medical Case Reports is an international, open access, peer reviewed Journal focusing exclusively on case reports covering all areas of clinical & medical sciences.

Visit the journal website at www.jclinmedcasereports.com

For reprints and other information, contact editorial office at info@jclinmedcasereports.com