

Mycobacterium kansasii liver abscess in a patient with HIV

Elsia Yoo*; Mohammed Sammanodi; Andrew Zhao; Michael Hocko

*Elsia Yoo

Lake Erie College of Osteopathic Medicine, Pennsylvania, USA

Email: elsia.yoo@gmail.com

Abstract

Mycobacterium kansasii is an acid-fast bacilli that is second only to *Mycobacterium avium* complex in causing non-tuberculous mycobacterial disease in the United States. While immunocompetent hosts typically only experience pulmonary manifestations, *M. kansasii* can become disseminated, especially in immunocompromised patients, and present with extrapulmonary features. This case report describes a HIV patient who presented with a hepatic abscess and concurrently low CD4 count and also includes a discussion on management issues and modifications.

Keywords

hepatic abscess; HIV/AIDS

Abbreviations

M.: *Mycobacterium*; NTM: non-tuberculosis mycobacterium; AFB: acid-fast bacilli; HAART: highly active antiretroviral therapy

Introduction

Mycobacterium kansasii is the second most commonly identified non-tuberculosis mycobacteria (NTM) in the United States. It is a slow-growing photochromogenic acid-fast bacilli with multiple subtypes that is typically found in tap water of endemic areas [1]. *M. kansasii* has been associated with clinically significant pulmonary and disseminated disease. Pulmonary disease with *M. kansasii* is the more common manifestation and typically presents as nodular, bronchiectatic or cavitary lung disease [2]. Disseminated NTM disease can be seen in addition to pulmonary disease in immunocompromised populations, especially in patients infected with human immunodeficiency virus [3]. Reported extrapulmonary sites of *M. kansasii* involvement include the intestines, liver, spleen, central nervous system, kidney, bone marrow, and pericardium [4]. Clinically, disseminated *M. kansasii* disease presents with fever, chills, night sweats, diffuse myalgias, pancytopenia, splenomegaly, and other signs and symptoms that are specific to site of involvement [5]. We report a case of liver abscess due to *M. kansasii* infection in a patient with HIV.

Case Presentation

A 38-year-old African American woman presented to the Sisters of Charity Hospital with a 3-week history of right upper quadrant abdominal pain. She also reported lightheadedness, night sweats, unintentional weight loss of twenty pounds, and generalized weakness. Patient reported ongoing

intravenous drug use but denied multiple sexual partners or recent sick contacts. She also reported having oral thrush and odynophagia for 2 months.

On examination she had a temperature of 38.7°C, blood pressure of 110/54 mmHg, heart rate of 114 beats/min, respiratory rate of 18 breaths/min, and oxygen saturation of 98% on room air. Oral mucous membranes demonstrated white scrapable lesions consistent with oral candidiasis. Abdominal examination revealed right upper quadrant tenderness. Her dental, chest, lung, skin and neurological examination were unremarkable.

A complete blood count revealed leukopenia (2400 cells/mm³), anemia (hemoglobin 7.7 mg/dl), and a platelet count of 130,000 cells/ μ L. She also had elevated serum alanine transaminase at 62 U/L and elevated serum aspartate transaminase at 168 U/L. Oral mucocutaneous cytology was positive for candida. Blood and urine cultures were obtained. Abdominal CT revealed a single fluid-filled lesion in the right hepatic lobe (Figure 1). Chest radiograph, abdominal ultrasound and hepatobiliary imaging were unremarkable. Blood and urine cultures were negative as were autoimmune markers and viral hepatitis panel. HIV testing was positive for HIV-1 with CD4 count of 25 cells/ μ L. Viral susceptibility was shown to be sensitive to all three drug classes of antiretroviral therapy. She was taken for CT-guided aspiration and biopsy of the liver lesion; a catheter was placed at this time.

The microbiology laboratory reported many acid-fast bacilli (AFB) confirmed as *Mycobacterium kansasii*. Susceptibility testing was performed and the isolate was shown to be sensitive to all routine antituberculous agents except pyrazinamide. She was started on daily doses of oral isoniazid, rifampin and ethambutol for 12 months. Patient also warranted prophylaxis for *Pneumocystis jirovecii* pneumonia, toxoplasmosis, and *Mycobacterium avium* complex; she was therefore promptly started on trimethoprim/sulfamethoxazole and azithromycin. Fluconazole for oral candidiasis was also added at this time.

Over the course of her antimycobacterial treatment, the patient tolerated the regimen well. Drainage from the liver abscess catheter gradually resolved over the course of 2 weeks of treatment. Subsequently CT guided removal of the catheter was performed. Repeat CT imaging showed a significant reduction in size of the liver abscess (Figure 2).

Patient remained afebrile and her general condition improved markedly. Given her clinical improvement, we elected to discharge the patient with plans to start highly active antiretroviral therapy (HAART) at a local HIV clinic.

Discussion

Nontuberculous mycobacteria are ubiquitous in the environment, rarely causing disease in immunocompetent individuals. However in immunocompromised patients such as HIV or transplant patients, NTM are important pathogens to consider [3]. There are more than 20 species of NTM and *M. kansasii* is the second most commonly identified NTM after *Mycobacterium avium* complex [1]. *M. kansasii* and other NTM will usually present as pulmonary disease with bronchiectasis or as a cavitary lesion [2]. Disseminated disease, while not uncommon, is a rarer manifestation usually presenting with fever, pancytopenia, and splenomegaly [6]. Development of liver abscess with *M. kansasii* is an unusual presentation of NTM disseminated disease only documented infrequently [5, 7, 8].

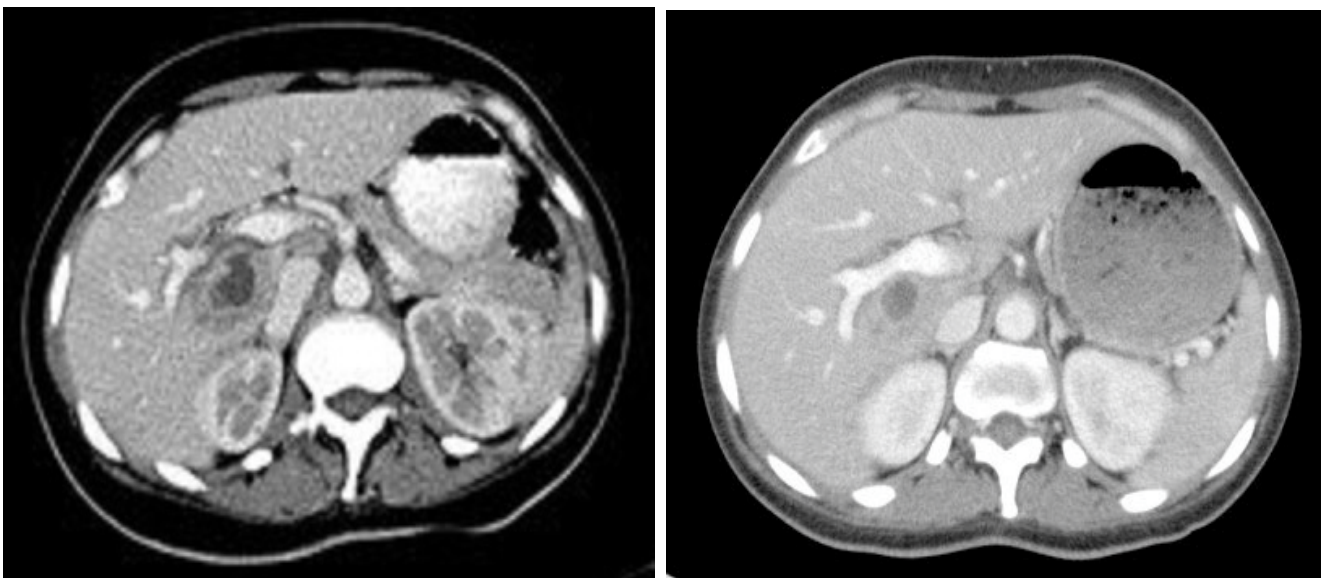
In this case report, our patient had both pancytopenia and a history of intravenous drug use on presentation concerning for an immunocompromised state. When evidence of HIV infection was confirmed, suspicion for a disseminated disease process increased given the patient's immunocompromised state. A hepatic abscess was identified and drained by abdominal CT. AFB was isolated and confirmed as *M. kansasii* from the hepatic abscess specimen.

We believe the source of *M. kansasii* in this case was likely the patient's intravenous drug use. However given the prevalence of NTM pulmonary disease, we also considered the possibility of radiographically occult asymptomatic pulmonary disease as a potential source [1]. Since there are no established treatment regimens for *M. kansasii* liver abscess, we followed guidelines pertaining to the treatment of NTM pulmonary disease from the American Thoracic Society, which suggest a three-drug combination of isoniazid 300 mg daily, rifampin 600 mg daily, and ethambutol 15 mg/kg per day [1].

Conclusion

Finally, HAART was not initiated at the time of the patient's liver abscess diagnosis due to the possibility of immune reconstitution inflammatory syndrome [9]. Due to concern of paradoxically worsening the *M. kansasii* liver abscess, we decided to start HAART later in the outpatient setting after adequate treatment with the antimycobacterial regimen.

Figures



References

1. Griffith D, Aksamit T, Brown-Elliott B, Catanzaro A, Daley C, Gordin F, et al. An Official ATS/IDSA Statement: Diagnosis, Treatment, and Prevention of Nontuberculous Mycobacterial Diseases. *Am J Respir Crit Care Med.* 2007;175(4):367-416.
2. Shitrit D, Priess R, Peled N, Bishara G, Shlomi D, Kramer M. Differentiation of *Mycobacterium kansasii* infection from *Mycobacterium tuberculosis* infection: comparison of clinical features, radiological appearance, and outcome. *Eur J Clin Microbiol Infect Dis.* 2007;26(10):679-684.
3. Campo R, Campo C. *Mycobacterium kansasii* Disease in Patients Infected with Human Immunodeficiency Virus. *Clinical Infectious Diseases.* 1997;24(6):1233-1238.
4. McGeedy S, Murphey S. Disseminated *Mycobacterium kansasii* infection. *Clinical Immunology and Immunopathology.* 1981;20(1):87-98.

5. Kaur P, Fishman J, Misdraji J, Varma M, Kotton C. Disseminated Mycobacterium kansasii infection with hepatic abscesses in a renal transplant recipient. *Transplant Infectious Disease*. 2011;13(5):531-535.
6. Mazor Y, Sprecher H, Braun E. Mycobacterium kansasii disseminated disease. *Isr Med Assoc J* 2010;12:121-2.
7. Massenkeil G, Opravil M, Salfinger M, von Graevenitz A, Luthy R. Disseminated Coinfection with Mycobacterium avium Complex and Mycobacterium kansasii in a Patient with AIDS and Liver Abscess. *Clinical Infectious Diseases*. 1992;14(2):618-619.
8. Casado J, Pintado V, Gomez-Mampaso E, Munoz V, Perez-Elias M. Mycobacterial liver abscess in a patient with AIDS. *Postgraduate Medical Journal*. 1998;74(869):181-183.
9. Burman W. Issues in the Management of HIV-Related Tuberculosis. *Clinics in Chest Medicine*. 2005;26(2):283-294.

Manuscript Information: Received: November 16, 2016; Accepted: March 07, 2017; Published: March 10, 2017

Authors Information: Elsia Yoo¹; Mohammed Sammanodi²; Andrew Zhao²; Michael Hocko²

¹Lake Erie College of Osteopathic Medicine, USA

²Department of Medicine at Sisters of Charity Hospital, University at Buffalo, USA

Citation: Yoo E, Sammanodi M, Zhao A, Hocko M. Mycobacterium kansasii liver abscess in a patient with HIV. *Open J Clin Med Case Rep*. 2017; 1231

Copy right statement: Content published in the journal follows Creative Commons Attribution License (<http://creativecommons.org/licenses/by/4.0>). © Yoo E 2017

Journal: *Open Journal of Clinical and Medical Case Reports* is an international, open access, peer reviewed Journal focusing exclusively on case reports covering all areas of clinical & medical sciences.

Visit the journal website at www.jclinmedcasereports.com

For reprints and other information, contact editorial office at info@jclinmedcasereports.com