

## Novel Schedule for Treatment of Inflammatory Breast Cancer

Raffaella Corvino; Francesca De Iuliis; Debora D'Aniello; Katia Cefali; Rosina Lanza; Susanna Scarpa\*

\*Susanna Scarpa

Department of Experimental Medicine, Sapienza University, Rome, Italy

Phone: 39 339 588 3081; Email: susanna.scarpa@uniroma1.it

### Abstract

Inflammatory breast cancer (IBC) is the most aggressive form of this tumor, with the clinical and biological characteristics of a rapidly proliferating disease. This tumor is always diagnosed at advanced stages, at least stage IIIB (locally advanced), so its management requires an integrated multidisciplinary approach with a systemic therapy followed by surgery and radiation therapy. Patients with IBC usually have a worse prognosis but the achievement of a pathologic complete response after neoadjuvant chemotherapy may have good rates of overall survival. We present the case of a 47 year old women with IBC, luminal B and with high proliferative index; she was successfully treated with a sequential schedule of chemotherapy (anthracyclines dose-dense/carboplatin+ taxane/Cyclophosphamide Methotrexate Fluorouracil), hormone-therapy, complementary radiotherapy and finally surgery until the achievement of a complete clinical and pathological response.

Luminal B inflammatory breast cancer with high proliferation index can benefit from sequential schedules of neoadjuvant chemotherapy and hormonal treatment and this can result in pathological complete response.

### Keywords

breast cancer; neoadjuvant chemotherapy; inflammatory breast cancer

### Abbreviations

IBC: inflammatory breast cancer; pCR: pathologic complete response; ER: estrogen receptor; PR: progesterone receptor; HER2: human epidermal growth factor receptor 2; CA: cancer antigen; CEA: carcino-embryonic antigen; CT: computed tomography; G-CSF: granulocyte colony-stimulating factor; CMF: Cyclophosphamide/Methotrexate/Fluorouracil; LHRH: luteinizing hormone-releasing hormone; MRI: magnetic resonance imaging; DIEP: deep inferior epigastric perforator; G: grade.

### Introduction

Locally advanced inoperable breast cancer includes stages IIIB (T4a involves the chest wall, T4b involves the skin, T4c involves the chest wall and the skin), stages IIIC (N3 with any T) and the inflammatory carcinoma or carcinomatous mastitis (T4d). Inflammatory breast cancer (IBC) is characterized by a diffuse hardening of the skin of the breast, a rapid onset of erythema, edema and *peau d'orange*, with or without an underlying palpable mass [1-3]. IBC usually develops at younger ages than the other breast cancers and it is at least stage IIIB (locally advanced). The management of locally advanced IBC requires an integrated multidisciplinary approach with a first systemic therapy followed by surgery and radiation therapy [1-3]. This type of tumor usually has a poor prognosis and a high risk of

local recurrence and of metastases. Accounting for approximately 10–15 % of locally advanced breast cancer, patients with IBC have 5-year overall survival rates of 34% to 47% [4]. Distant metastases are detected at the time of diagnosis in about 4 % of all breast cancer patients, but are observed in 14 % of T3 and in 26 % of T4 patients with IBC [5].

There is no standard chemotherapy regimen for IBC, usually patients receive the following setting of adjuvant chemotherapy: combined or sequential anthracyclines and taxanes for at least 6-8 cycles. This chemotherapy regimen has been associated with higher rate of pathologic complete response (pCR) and better survival outcome, compared with other agents [6].

Many studies on neoadjuvant therapy included heterogeneous population of patients with breast cancer with different biological characteristics, but only few patients with IBC. The addition of a platinum compound (carboplatin) to neoadjuvant chemotherapy demonstrated an increase in pCR rate in triple-negative IBC [7].

## Case Presentation

We present the case of a 47 year old women with a bilateral inflammatory breast cancer: right breast showed tough and necrotic skin, ulcerated in the outer quadrants, with nipple retracted and axillary lymph node package; left breast had *peau d'orange* and lymphadenopathy.

A diagnostic mammogram and ultrasound analysis showed a widespread structural alteration in the right breast, with an appearance grossly pseudo-nodular at the level of the axillary extension cable (diameter 24mm); at the same time a diagnostic mammogram showed a nodular lesion (diameter 7 mm) in the upper outer quadrant of the left breast, further more an axillary adenopathy was evident (diameter 17mm) in the left breast.

Core biopsy analysis of left breast lesion diagnosed an invasive ductal breast carcinoma, grade G3, immunohistochemistry indicated estrogen receptor (ER) 90% positive, progesterone receptor (PR) 60% positive, ki67 60% positive, human epidermal growth factor receptor 2 (HER2) negative, with the classification of luminal B. A core needle biopsy of lateral and contra lateral axillary lymph nodes was performed revealing metastatic repetition. Core biopsy of right breast was not performed. Plasma tumor markers were evaluated: cancer antigen (CA) 15-3 was 31, 8 U/mL and carcino-embryonic antigen (CEA) was 2.6 ng/mL. Computed tomography (CT) scan showed no evidence of metastatic disease outside of the breast and of the axillae, confirming a locally advanced IBC (cT4d, cN2).

The patient underwent neoadjuvant chemotherapy consisting of Epirubicin 90 mg/mq and Cyclophosphamide 600 mg/mq p1q15 with granulocyte colony-stimulating factor (G-CSF) as prophylaxis of chemotherapy-induced febrile neutropenia. After four cycles of chemotherapy the patient achieved a partial response (50%) determined by clinical and instrumental examination. The patient then received four cycles of chemotherapy with carboplatin AUC2 and Paclitaxel 80 mg/mq p1,8,15 q28, followed by additional clinical response.

Considered the extent of the disease, the excellent response to chemotherapy and the good patient compliance, another 3 cycles of chemotherapy were performed, according to the scheme Cyclophosphamide/Methotrexate/Fluorouracil (CMF) p1,8 q28, which finished on March 2015 with low

grade (G) of toxicity and a complete clinical response of the patient. The adverse events described by the patients were the following: anemia G1, neutropenia G1 and alopecia G4.

A diagnostic mammogram of the right and left breast was performed on April 2015 and showed only an increase in density of the right breast and CT scan was negative. The patient received endocrine therapy with Letrozole and luteinizing hormone-releasing hormone (LHRH) agonist with no toxicity in the patient. A magnetic resonance imaging (MRI) performed on June 2015 showed complete radiologic response to treatment. Radical right breast mastectomy and axillary lymph node dissection were performed on October 2015, together to right breast reconstruction with micro vascular deep inferior epigastric perforator (DIEP) flap. At the same time, the patient underwent left quadrantectomy with left sentinel node control plus remodeling of left breast. Complementary radiotherapy was done to the left breast to a total dose of 66Gy and didn't determine any toxicity. The histopathological analysis of the right breast tissue indicated the presence of single regressive tumor cells with the following characteristics: ER 90%, PgR 1%, ki67 3%, HER2 negative; no cancer cells were observed in the lymph nodes. Left breast and left sentinel node showed no evidence of residual carcinoma. These data demonstrated a pathological complete response of the patient. Our patient is actually free of disease, and she is continuing hormonal treatment with aromatase inhibitors without side effects.

## Discussion

Inflammatory breast cancer is extremely rare and more aggressive than the other types of breast cancer. The risk of contralateral breast cancer following IBC is rare, there were only few case reports of bilateral IBC reported in the literature [8], in fact the tumor here described is the only case followed by our Department.

Nowadays, primary systemic treatment is considered the standard of care for breast cancer patients with locally advanced and inflammatory breast cancer. Stage III IBC is often characterized by a worse prognosis than stage III non-inflammatory tumors, with increased loco-regional and distant recurrence rates [9, 10]. Although the risk of contralateral breast cancer following IBC is rare [8], our patient presented a bilateral IBC.

The standard treatment of IBC consists of neo-adjuvant chemotherapy followed by modified radical mastectomy, radiotherapy or chemo-radiotherapy and eventually endocrine therapy, when appropriate [11, 12]. A pCR after neo-adjuvant chemotherapy has been consistently associated with improved outcomes and benefit in terms of overall survival [13], regardless of biological breast cancer subtype; our patient developed a good response after neo-adjuvant chemotherapy.

Unfortunately, despite the progress in breast cancer treatment, the survival of patients with IBC still remains at low rates, with a 5-year overall survival of 46% and a disease-free survival of 40% [14]. On the contrary, our experience demonstrated that the presented case of luminal B inflammatory breast cancer with high proliferation index benefitted from sequential schedules of chemotherapy and hormonal treatment. Our patient obtained a pathological complete response after less than 1 year of treatment, without affecting her quality of life, very rare for a bilateral inflammatory breast cancer.

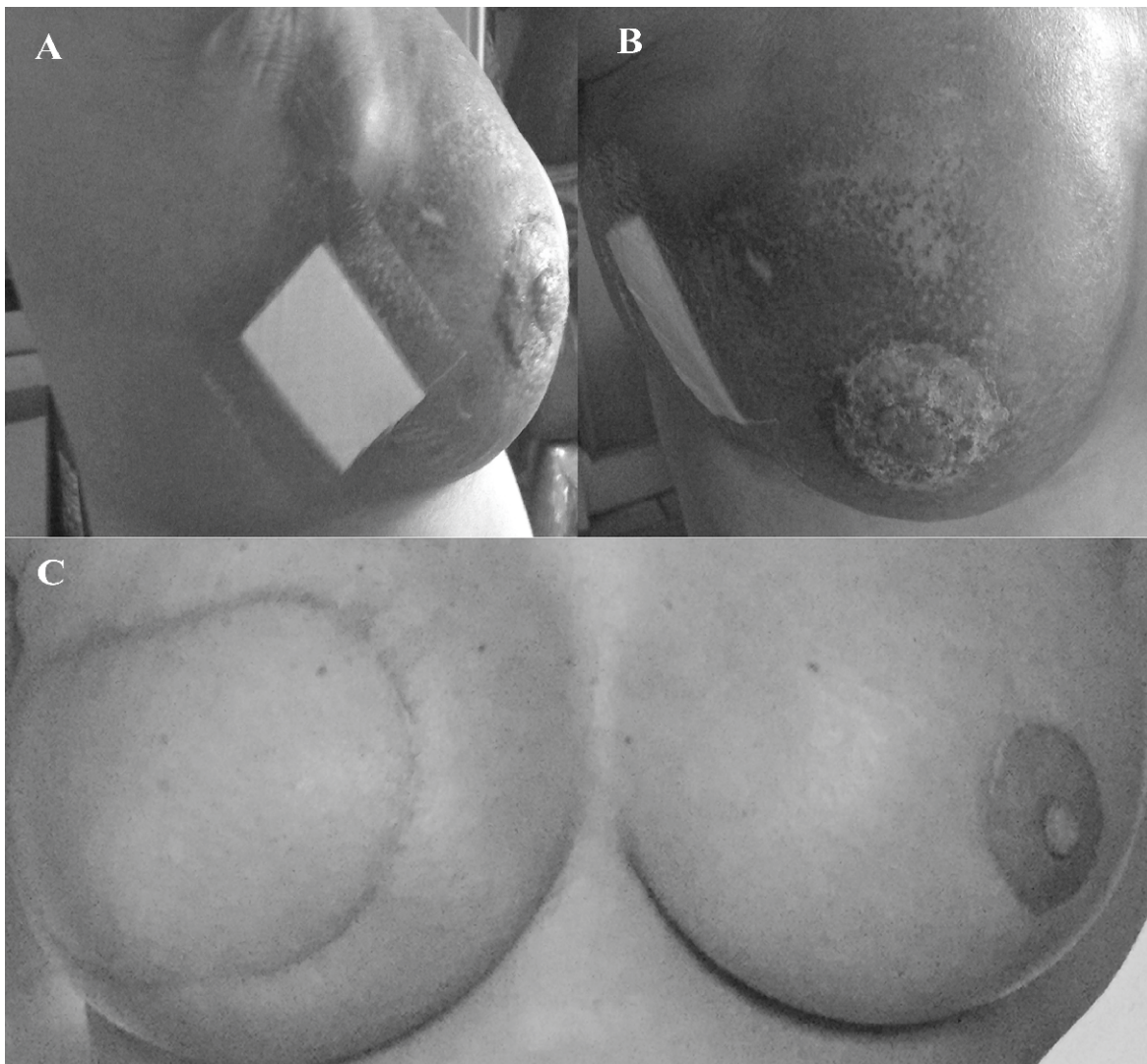
Our patient achieved an excellent result with chemotherapy, using the most active drugs (anthracycline and taxane) but with a peculiar schedule that ensures a good tolerability. In fact the only

observed toxicities were low, the only severe toxicity was alopecia G4. The haematological toxicity, usually caused by anthracycline, was avoided thanks to colony stimulating factors.

Our patient responded very well with a high chemosensitivity to the therapy, therefore further sequential chemotherapy schemes were performed and led to a clinical and instrumental pCR. The subsequent endocrine-therapy consolidated the results and finally the surgery response was excellent. Due to the optimal response after anthracycline and taxanes, we have chosen to treat our patient sequentially with CMF schedule, since a large trial demonstrated efficacy of CMF for IBC, with an improvement of 8-15% of the 10-year overall survival by the addition of CMF to radiotherapy and tamoxifen [15]. Other trials showed that adding anthracyclines and taxanes led an increase of the 5-year survival of about 70 % for locally advanced cancer and of about 40 % for IBC [14, 16].

Our patient was HER2 negative, so she has not been treated with target therapy, but has obtained a pCR only with chemotherapy and hormonal therapy, accordingly with her molecular phenotype. Our patient is still free of disease, and she is continuing only hormonal treatment with aromatase inhibitors without side effects.

## Figures



**Figure 1:** Images of starting point of right breast (A-B) and of final result (C) of breast from a case of inflammatory breast cancer.

## Conclusion

In conclusion our patient obtained a pathological complete response after less than 1 year of treatment, without affecting her quality of life and with an optimal esthetic effect, very rare for a bilateral inflammatory breast cancer.

## References

1. Dawood S, Merajver SD, Viens P, Vermeulen PB, Swain SM, Buchholz TA, et al. International expert panel on inflammatory breast cancer: consensus statement for standardized diagnosis and treatment. *Ann Oncol* 2011;22:515-523.
2. Dawood S, Cristofanilli M. Inflammatory breast cancer: what progress have we made? *Oncology* 2011;25:264-270.
3. El Saghir NS, Eniu A, Carlson RW, Aziz Z, Vorobiof D, Hortobagyi GN. Breast Health Global Initiative Systemic Therapy Focus Group. Locally advanced breast cancer: treatment guideline implementation with particular attention to low- and middle-income countries. *Cancer* 2008;113:2315-2324.
4. Rueth NM, LinHY, Bedrosian I, Shaitelman SF, Ueno NT, Shen Y, et al. Underuse of Trimodality Treatment Affects Survival for Patients With Inflammatory Breast Cancer: An Analysis of Treatment and Survival Trends From the National Cancer Database. *J Clin Oncol* 2014; 32: 2018-2024.
5. Budach W, Matuschek C, Bölke E, Dunst J, Feyer P, Fietkau R, et al. Therapy for locally advanced and inflammatory breast cancer, as well as local therapy in cases with synchronous distant metastases. *Strahlenther Onkol* 2015; 191: 634.
6. Cuppone F, Bria E, Carlini P, Milella M, Felici A, Sperduti I, et al. Taxanes as primary chemotherapy for early breast cancer. Meta-analyses of randomized trials. *Cancer* 2008;113: 238-246.
7. Anderson WF, Schairer C, Chen BE, Hance KW, Levine PH. Epidemiology of inflammatory breast cancer. *Breast Dis* 2005;22:9-23.
8. Kurtz J, Halaharvi D, Sarwar S, Cripe M. A case of bilateral inflammatory breast cancer: a case report. *The Breast J*. 2016; 22: 342-346.
9. Anderson WF, Chu KC, Chang S. Inflammatory breast carcinoma and non-inflammatory locally advanced breast carcinoma: distinct clinicopathologic entities? *J Clin Oncol* 2003;21:2254-2259.
10. Dawood S, Ueno NT, Valero V, Woodward WA, Buchholz TA, Hortobagyi GN, et al. Differences in survival among women with stage III inflammatory and non-inflammatory locally advanced breast cancer appear early: a large population-based study. *Cancer* 2011;117:1819-1826.
11. Denu RA, Hampton JM, Currey A, Anderson RT, Cress RD, Fleming ST, et al. Influence of patient, physician, and hospital characteristics on the receipt of guideline-concordant care for inflammatory breast cancer. *Cancer Epidemiol* 2016; 40: 7-14. doi: 10.1016/j.canep.2015.11.003.
12. Bellière-Calandry A, Benoît C, Dubois S, Moreau J, Achard JL, Loos G, et al. Salvage concomitant chemo-radiation therapy for non-metastatic inflammatory breast cancer after chemotherapy failure. *Cancer Radiother* 2015; 19: 739-745. doi: 10.1016/j.canrad.2015.06.020.
13. Von Minckwitz G, Untch M, Blohmer JU, Costa SD, Eidtmann H, Fasching PA, et al. Definition and Impact of Pathologic Complete Response on Prognosis After Neoadjuvant Chemotherapy in Various Intrinsic Breast Cancer Subtypes. *J Clin Oncol*. 2012;30:1796-1804.
14. Rehman S, Reddy CA, Tendulkar RD. Modern outcomes of inflammatory breast cancer. *Int J Radiat Oncol Biol Phys* 2012; 84: 619-624. doi: 10.1016/j.ijrobp.2012.01.030.

15. Bartelink H, Rubens RD, van der Schueren E, Sylvester R. Hormonal therapy prolongs survival in irradiated locally advanced breast cancer: a European Organization for Research and Treatment of Cancer Randomized Phase III Trial. *J Clin Oncol* 1997;15:207-215.
16. Scotti V, Desideri I, Meattini I, Di Cataldo V Di, Cecchini S, Petrucci A, et al. Management of inflammatory breast cancer: focus on radiotherapy with an evidence-based approach. *Cancer Treat Rev* 2013;39:119-124.

**Manuscript Information:** Received: July 13, 2016; Accepted: October 19, 2016; Published: October 22, 2016

**Authors Information:** Raffaella Corvino<sup>1</sup>; Francesca De Iuliis<sup>2</sup>; Debora D'Aniello<sup>1</sup>; Katia Cefali<sup>1</sup>; Rosina Lanza<sup>1</sup>; Susanna Scarpa<sup>2\*</sup>

<sup>1</sup>Department of Gynecology Obstetrics and Urology, Sapienza University, Rome

<sup>2</sup>Department of Experimental Medicine, Sapienza University, Rome

**Citation:** Corvino R, De Iuliis F, D'Aniello D, Cefali K, Lanza R, Scarpa S. Novel schedule for treatment of inflammatory breast cancer. *Open J Clin Med Case Rep.* 2016; 1175

**Copy right statement:** Content published in the journal follows Creative Commons Attribution License (<http://creativecommons.org/licenses/by/4.0>). © Scarpa S 2016

**Journal:** Open Journal of Clinical and Medical Case Reports is an international, open access, peer reviewed Journal focusing exclusively on case reports covering all areas of clinical & medical sciences.

Visit the journal website at [www.jclinmedcasereports.com](http://www.jclinmedcasereports.com)

For reprints & other information, contact editorial office at [info@jclinmedcasereports.com](mailto:info@jclinmedcasereports.com)