

Complete ICD Removal and Implantation of Subcutaneous Device in a Patient with Pocket Infection and Endocarditis: Three Years Follow-Up

Luca Santini; Vittoria Doldo^{*}; Valentina Schirripa; Federico Mercanti; Maria Gugliotta; Germana Panattoni; Valeria Cammalleri; Domenico Sergi; Giulia Magliano; Giovanni B Forleo; Alessandra Ricciardi; Pasquale Sordillo; Francesco Romeo

*Vittoria Doldo

Cardiology Division, G.B.Grassi Hospital, Rome, Italy. Email: doldovittoria@virgilio.it

Abstract

Infections related to cardiac implantable electronic devices (CIEDs) are increasing in prevalence and carry substantial morbidity and mortality. In this report we describe the case of a patient with alcoholic dilated cardiomyopathy affected by an evident ICD pocket infection and related right side endocarditis. The patient, submitted to a complete device removal combined with long lasting intravenous antibiotic treatment, successively underwent to implantation of an entirely subcutaneous ICD (s-ICD). The decision to implant an s-ICD was taken in order to avoid ICD reinfection and endocarditis recurrence. This report is, to our knowledge, one of the first case of S-ICD implantation in a patient undergone to lead extraction due to an active diagnosis of endocarditis and complicated by subclavian thrombosis.

Keywords

Subcutaneous implantable cardioverter-defibrillator; Endocarditis; Pocket infection; Sudden cardiac death

Abbreviations

CIEDs: Cardiac Implantable Electronic Devices; ICD: Implantable Cardioverter Defibrillator; s-ICD: subcutaneous Implantable Cardioverter Defibrillator; LVEF: Left Ventricular Ejection Fraction; VT: Ventricular Tachycardia

Introduction

Infections related to cardiac implantable electronic devices (CIEDs) are increasing in prevalence and carry substantial morbidity and mortality [1-2]; one of the most critical is represented by lead's infection or device-related endocarditis.

We describe the case of a patient affected by an evident ICD pocket infection and related right side endocarditis, submitted to a complete device removal combined with long lasting intravenous antibiotic treatment [3] and following subcutaneous ICD (s-ICD) implantation. The decision to implant an s-ICD was taken in order to avoid ICD re-infection and endocarditis recurrence.

Case Report

A 54 years old male was diagnosed with alcoholic dilated cardiomyopathy and underwent to a single chamber ICD implantation for primary prevention of sudden cardiac death. After four years the

device replacement was performed in the same center because of the battery end of life. Two years later the patient showed mild skin erosion with presence of pain, swelling, erythema and leaking pus at the site of implantation without lead's exposure, fever or other symptoms. Even if blood cultures were performed with negative results, the pocket swab was positive for *Staphylococcus caprae* and an adequate antibiotic therapy was administered. The patient has been recovered in the same center and undergone to a conservative procedure in order to clean the pocket and to replace the generator deeper under the pectoral muscle. According to the documentation the questionable choice of not performing a complete device and lead removal was due to the absence of the device externalization and systemic symptoms. He was then discharged with antibiotic therapy, and the surgical wound and inflammatory markers continually re-evaluated. After three months he returned with lead's exposure and again leaking-pus: another pocket swab was then performed and its result was positive for methicillin sensitive *Staphylococcus aureus* (MSSA). At this time the patient was referred to our center where he began antibiotic therapy with ampicillina/sulbactam and gentamicin. We perform a transthoracic echocardiogram, followed by a transesophageal echocardiogram describing the presence of vegetations on the aortic valve cusp lower than 25 mm: the diagnosis of endocarditis was made (Fig 1). Furthermore at the beginning of the antibiotic treatment a PET/TC with contrast was also performed [4] showing an uptake in left pectoral region related to the inflammatory process and thrombosis of subclavian vein and anonymous left trunk (Fig 2). The patient was completely asymptomatic and few days later underwent to the complete ICD removal. A transvenous single coil lead extraction was performed by using laser sheaths and the system was totally and successfully removed without any complications. The infection's diagnosis was confirmed on the devices by culture post-explantation. The patient was then transferred to the department of infectious diseases where he stayed for 6 weeks under monitoring telemetry and appropriate antibiotic therapy with ampicillina/sulbactam and gentamicin (80 mg x 2/die for 6 weeks). Then a new transesophageal echocardiogram was performed, and an hyperechogenic formation adherent to chordate tendineae and moving in the right ventricle was described. For this condition, antibiotic treatment with ampicillin/ sulbactam has been continued and oral anticoagulation with warfarin started. Later patient was re-evaluated with PET/TC showing completed resolution of tracer uptake and thrombosis. Despite a complete recover of LVEF, as the patient has been stopping with alcohol abuse, we decided to perform the ICD re-implantation because of the finding of fast VT episodes in the memory of the old ICD. On the basis of the high risk of recurrence of endocarditis, of new system's infections and for the recent venous thrombotic complication, we decided to implant a subcutaneous device. Forty-four days after the extraction of the intravenous system our patient was indeed implanted with s-ICD (Boston Scientific). No complication occurred during the procedure and immediately after. A specific antibiotic therapy was continued to prevent re-infection and two days after the procedure the patient was discharged with the indication to continue antibiotic therapy for other two weeks. No complication occurred and patient showed a good acceptance of the s-ICD. After a week of ICD implantation, the surgical wound was re-evaluated and there were no signs of infection or inflammation (Fig. 3). Moreover one month following the implantation, control device was performed and showed correct device functioning and the absence of arrhythmic events or delivered shocks. Consecutive follow-up for three years have been performed showing similar results to the previous one.

Discussion

This is to our knowledge one of the first cases of s-ICD implantation in a patient undergone to lead's extraction due to endocarditis complicated by subclavian thrombosis. This report perfectly shows how the use of s-ICD may be an opportunity in patients who need to re-implant CIEDs after their extraction for infective issues [5]. In this group of patients indeed a standard trans-venous approach could be more dangerous because of the increased risk of re-infection with the subsequent need of a second lead's extraction procedure. Lead's extraction is an highly challenging intervention with major complication rates of about 1% and a mortality risk rate of about 0.3% also in experienced centers [6]. Moreover a new trans-venous implant could also potentially lead to recurrence of venous thrombosis. s-ICD avoids the need of electrodes inside the heart and can provide clinical advantages, especially among these subgroups of patients reducing significantly the risk of recurrent vascular and infective complications related to the replacement of the device [7-8-9].

Figures

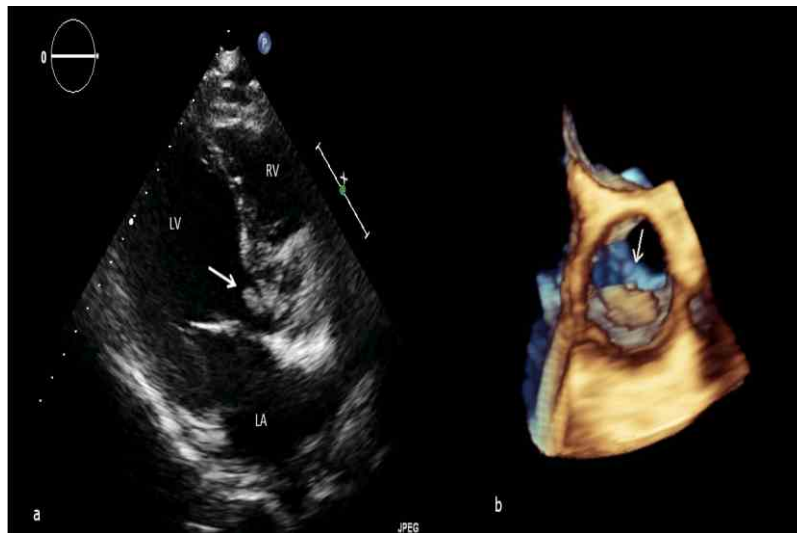

Figure 1. (a) Transthoracic parasternal long axis view showing an endocarditic mass (arrow) adherent on the ventricle side of the aortic cusp. LA: left atrium; LV: left ventricle; RV: right ventricle (b) Three-dimensional transesophageal echocardiogram (aortic view) showing the infectious mass adherent to the ventricular side of the right-coronary cusp and prolapsing in the aortic lumen during systole.

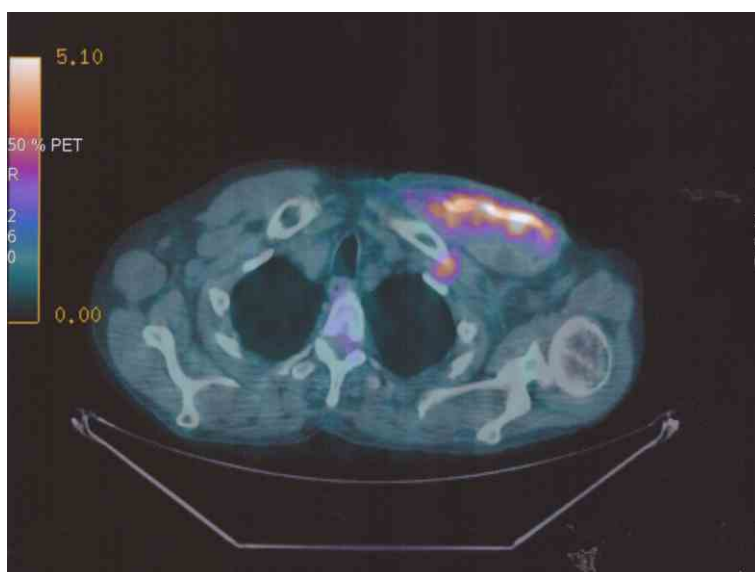


Figure 2. PET/TC showing the uptake of the left pectoral region and the thrombosis of subclavian vein and anonymous left trunk

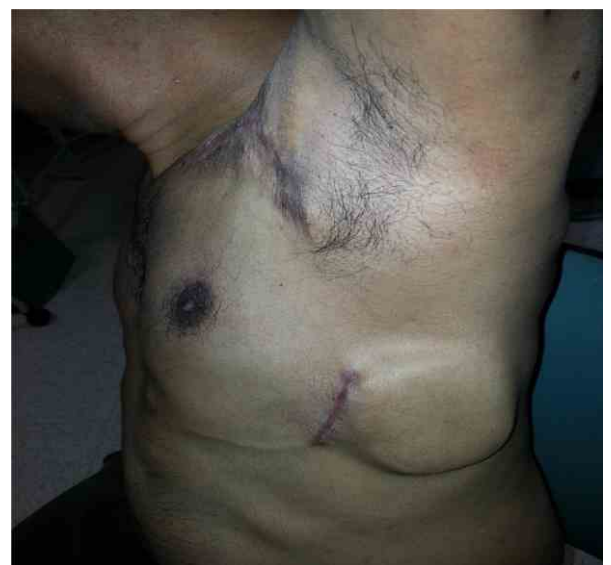


Figure 3. surgical wound after a week from the ICD implantation

References

1. Nery PB, Fernandes R, Nair GM, Sumner GL, Ribas CS, Menon SM et al. Device-related infection among patients with pacemakers and implantable defibrillators: incidence, risk factors, and consequences. *J Cardiovasc Electrophysiol*. 2010 Jul;21(7):786-90.
2. Bongiorno MG, Di Cori A, Soldati E, Zucchelli G, Segreti L, Solarino G et al. Iatrogenic risk of permanent pacemaker and defibrillator implantation. *G Ital Cardiol (Rome)*. 2009 Jun;10(6):395-406.
3. Bongiorno MG, Marinskis G, Lip GY, Svendsen JH, Dobreanu D, Blomström-Lundqvist C et al. How European centers diagnose, treat, and prevent CIED infections: results of an European Heart Rhythm Association survey. *Europace* 2012 Nov;14(11):1666-9.
4. Brinker J. Imaging for Infected Cardiac Implantable Electronic Devices. *J Am Coll Cardiology* 2012 May 1; 59(18): 1626-8.
5. McLeod CJ, Boersma L, Okamura H, Friedman PA. The subcutaneous implantable cardioverter defibrillator: state of the art review. *EurHeart J*. 2015 Oct 29. pii: ehv507.
6. Sohal M, Williams SE, Arujuna A, Chen Z, Bostock J, Gill JS et al. The current practice and perception of cardiac implantable electronic device transvenous lead extraction in the UK. *Europace*. 2013 Jun;15(6):865-70.
7. Viganego F, O'Donoghue S, Eldadah Z, Shah MH, Rastogi M, Mazel JA et al. Effect of early diagnosis and treatment with percutaneous lead extraction on survival in patients with cardiac device infections. *Am J Cardiol*. 2012 May 15;109(10):1466-71.
8. Tien Siang, Eric Lim, Boon Yew Tan, KahLeng Ho, Lim CY, Teo WS, Ching CK. Initial experience of subcutaneous implantable cardioverter defibrillators in Singapore: a case series and review of the literature. *Singapore Med Journal* 2015; 56(10):580-585.
9. Boersma L, Burke MC, Neuzil P, Lambiase P, Friehling T, Theuns DA et al. Infection and mortality after implantation of a subcutaneous ICD after transvenous ICD extraction. *HeartRhythm*. 2016 Jan;13(1):157-64.

Manuscript Information: Received: January 05, 2015; Accepted: March 18, 2016; Published: March 21, 2016

Authors Information: Luca Santini¹; Vittoria Doldo^{2*}; Valentina Schirripa¹; Federico Mercanti²; Maria Gugliotta²; Germana Panattoni²; Valeria Cammalleri²; Domenico Sergi²; Giulia Magliano²; Giovanni B Forleo²; Alessandra Ricciardi³; Pasquale Sordillo³; Francesco Romeo²

¹Cardiology Division, G.B.Grassi Hospital, Rome, Italy

²Department of Internal Medicine, Division of Cardiology, University of Rome "Tor Vergata", Italy

³Department of Internal Medicine, Division of Infectious Diseases, University of Rome "Tor Vergata", Italy

Citation: Santini L, Doldo V, Schirripa V, Mercanti F, Gugliotta M, Panattoni G et al. Complete ICD removal and implantation of subcutaneous device in a patient with pocket infection and endocarditis: three years follow-up. *Open J Clin Med Case Rep*. 2016; 1092

Copy right Statement: Content published in the journal follows Creative Commons Attribution License (<http://creativecommons.org/licenses/by/4.0>). © **Doldo V 2016**

Journal: Open Journal of Clinical and Medical Case Reports is an international, open access, peer reviewed Journal focusing exclusively on case reports covering all areas of clinical & medical sciences.

Visit the journal website at www.jclinmedcasereports.com

For reprints & other information, contact editorial office at info@jclinmedcasereports.com